

# Hereditary eye disease in dogs

Revised by Sheila Crispin, August 2018

With acknowledgements to past and present members of the Eye Panel and Eye Panel Working Party and with grateful thanks to Dr Cathryn Mellersh and the Animal Health Trust



# Hereditary eye disease in dogs

## PART I

## Clinical Examination for inherited eye disease

By Sheila Crispin

**The main purpose of the British Veterinary Association/Kennel Club/International Sheep Dog Society (BVA/KC/ISDS) Eye Scheme is to ensure that there is no clinical evidence of hereditary eye disease in dogs that are to be used for breeding. A secondary purpose is to identify breed-related problems which may be inherited, especially if they have welfare implications for the dog. Following examination of the eye an Eye Examination Certificate is issued which records the inherited eye disease status (Schedule A) relevant to the breed being examined as either ‘clinically unaffected’ or ‘clinically affected’ together with any additional comments about other clinical findings. In breeds in which primary glaucoma is recognised clinical examination is supplemented by examination of the drainage angle—gonioscopy (primary closed angle glaucoma) or measurement of intraocular pressure—tonometry (primary open angle glaucoma). In addition, clinical examination of puppies when they are still part of a litter (litter screening) can be used to identify signs of congenital/early onset inherited eye disease in affected puppies. When new potentially inherited conditions are considered for listing under Schedule A, their inclusion is based on the scientific evidence including a clinical prevalence of at least 1% over a minimum three-year period and/or the peer-reviewed scientific literature.**


Over the years, since its inception in the 1960s, the Eye Scheme has been expanded to include assessment not just of the eye, but also of adjacent (adnexal) structures such as the eyelids. The result of this expansion is that certification under the Eye Scheme has important subsidiary benefits; notably, recording anomalies (findings of no clinical significance) and abnormalities (findings of potential or actual clinical significance) whatever their origin. Examples are provided at the end of this section (Part I).

It is clearly sensible for all dogs (pure bred and cross bred) which are to be used for breeding to be examined under the Eye Scheme prior to being bred from, as this is the simplest way of identifying breed-related and potentially inherited problems. Advice on the frequency of re-testing is provided each time the dog is examined under the Eye Scheme. Examination and certification of older dogs, usually those no longer used for breeding, should be regarded as essential, because longitudinal information collected over time is a crucial means of providing owners and breeders with the information that they need in order to make informed breeding decisions and, in addition, a reduced fee provides a financial incentive for certification of dogs aged eight years and older. In summary, examination of the older dog is recommended for a number of reasons:

- Enabling longitudinal information to be collected. A longitudinal study is an observational research method in which data is gathered for the same subjects repeatedly over a period of time;

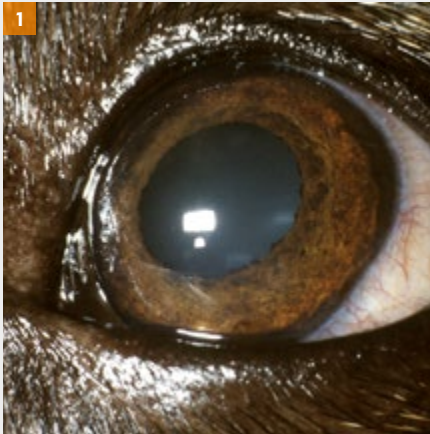
- Ensuring that the dog remains free of the inherited eye diseases listed for the breed being examined under Schedule A of the Eye Scheme. A number of inherited eye problems may only be detected later in life (for example, various types of hereditary cataract and some forms of progressive retinal atrophy);
- Indicating whether late onset, potentially inherited, conditions are emerging in older animals;
- Identifying age-related ocular and generalised diseases with ocular manifestations, some of which may need treatment.

Further information is provided in *Why should we check the eyes of older dogs?* (available from [www.bva.co.uk/chs](http://www.bva.co.uk/chs)).

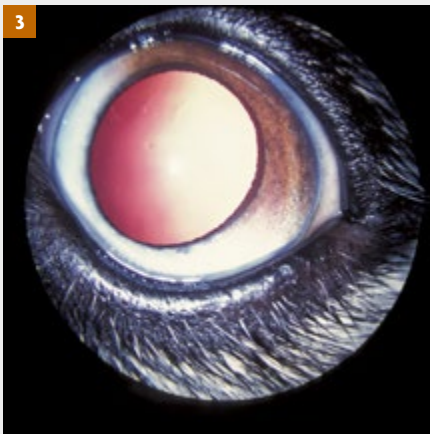
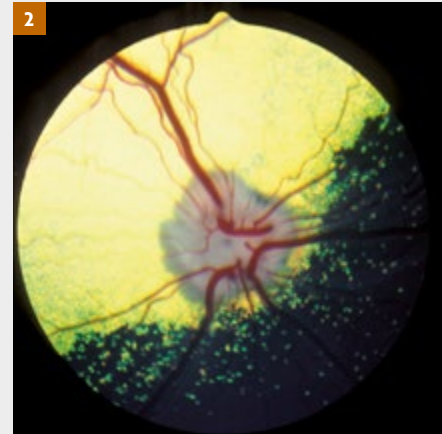




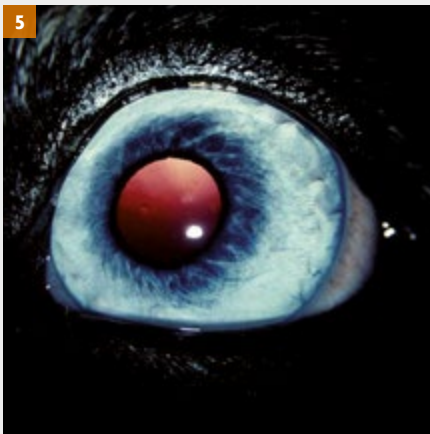
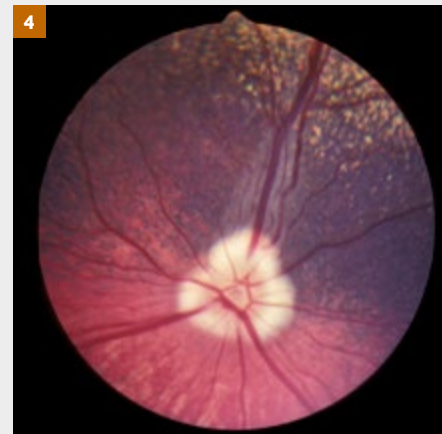## The normal eye




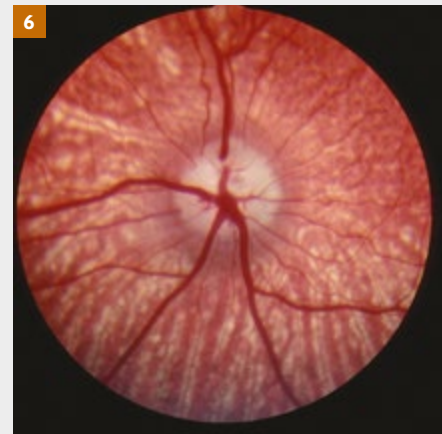
**1:** Normal adult eye of a Border Collie with a pigmented iris. **2:** Ocular fundus of that eye, showing the tapetal fundus (yellow) dorsally and heavily pigmented non-tapetal fundus ventrally.



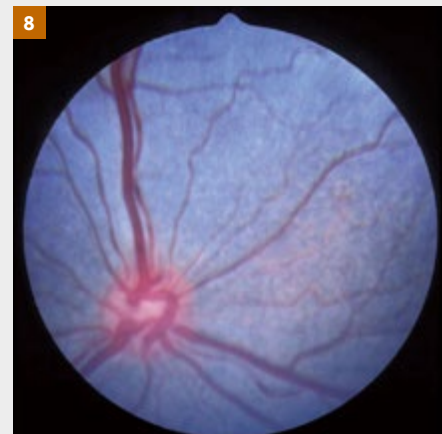**3:** Normal adult eye of a Crossbred dog with variations of pigmentation (heterochromia) in different sectors of the iris. **4:** Ocular fundus of that eye. Note that there is less pigment ventrally, corresponding with the area of reduced pigmentation in the iris.



**5:** Subalbinotic eye of a normal adult Border Collie. **6:** Ocular fundus of that eye. Both retinal and choroidal vessels are visible and there is no tapetum.



**7:** Normal ocular fundus of the eye of the Border Collie puppy pictured on the left. **8:** The eyes of newborn puppies are not fully developed at birth and the tapetum has not yet formed in this five-week-old puppy.



The inherited eye conditions currently certified under the Eye Scheme are reviewed in Part I of this article, together with examples of some other conditions of the eye and adnexa which may be inherited, as well as other examples of non-inherited conditions. The potentially inherited and non-inherited conditions are currently recorded in the middle section of the certificate.

Inherited eye disease status (Schedule A) is recorded in the bottom section of the certificate, as congenital (present from birth) and non-congenital (acquired later in life) in type. This simple classification is not entirely satisfactory as the eyes of puppies cannot be examined until the puppy is at least 4 weeks of age, so there is a presumption that abnormalities viewed at this stage are of congenital origin, whereas it is possible that some of the conditions identified may actually be neonatal rather than congenital. In addition, because the eye is immature at birth, it is possible that some developmental conditions may not be apparent at litter screening (puppies of up to 12 weeks of age) and others may become less obvious (for example, Collie eye anomaly) because of postnatal maturation. It is more rational to describe inherited congenital conditions as those identifiable during the neonatal stage (congenital/neonatal).

In summary, clinical examination for certification (Schedule A conditions) under the BVA/KC/IDS Eye Scheme includes:

1. Litters of puppies in breeds with congenital/neonatal inherited ocular disease (Litter Screening Eye Examination Certificate);
2. All dogs, whether purebred or cross bred, before they are used for breeding and when they are subsequently bred from (Eye Examination Certificate). For dogs that are bred from year on year (for example, popular sires), annual re-examination (Eye Examination Certificate) is required throughout the dog's breeding life;
3. Breeds in which primary glaucoma is recognised require additional assessment as part of certification (Eye Examination Certificate) under the Eye Scheme. Clinical examination should be supplemented by gonioscopy to assess the drainage angle in breeds susceptible to primary closed angle/angle closure glaucoma and tonometry to measure the intraocular pressure in breeds susceptible to primary open angle glaucoma. Both these procedures may need to be repeated in later life;
4. Dogs of eight years of age or older should be examined, at a reduced fee, in order to check ocular and general health, to provide valuable longitudinal data and to ensure that later onset inherited conditions are recorded accurately (Eye Examination Certificate).

## Inherited eye diseases certified under the Eye Scheme Schedule A

### Glaucoma

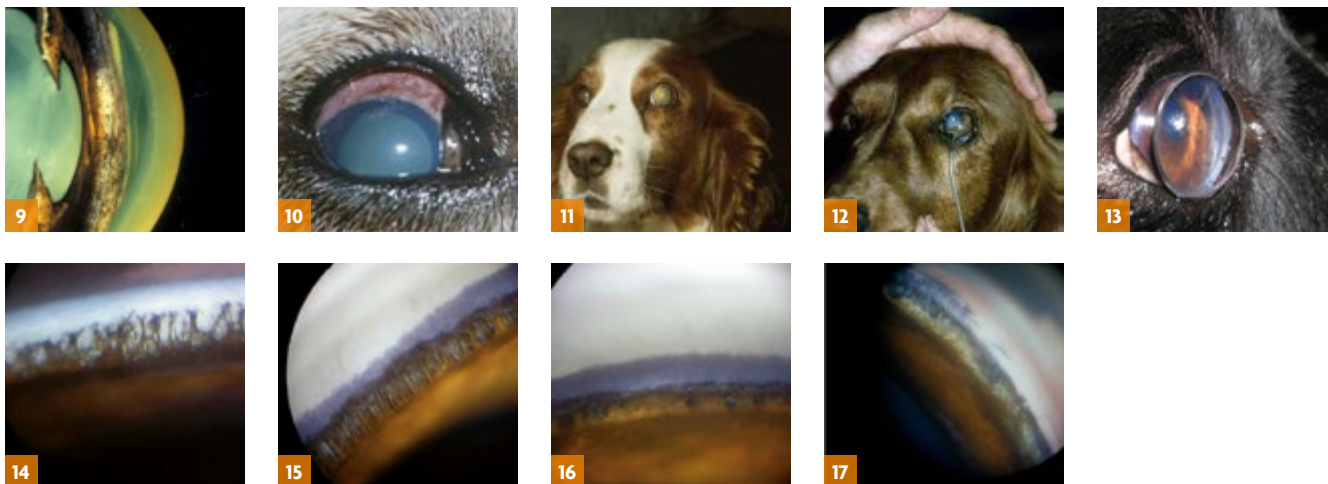
Glaucoma is the term used to describe the effects of a sustained pathological elevation of intraocular pressure. In normal eyes the rate of aqueous humour formation and the rate of aqueous outflow are in balanced equilibrium and the normal canine intraocular pressure (IOP) measured with an applanation or rebound electronic tonometer is approximately 10–25mmHg. The clinical features shown are those which are the result of structural ocular damage and the consequent visual impairment or blindness. In particular, it is the damage to the retinal ganglion cells and axons of the optic nerve, particularly the prelaminar portion, which is the most significant feature in sight loss. Once the process of retinal ganglion cell and optic nerve degeneration has begun, the most that appropriate therapy can achieve is slowing down the loss of sight.

Glaucoma is not a single disease entity, but rather a degenerative process with a number of possible causes and a final common pathway. Two broad categories of glaucoma are recognised—primary and secondary. In primary glaucoma there is no antecedent intraocular disease and, although the aetiology is complex, all the canine primary glaucomas are due to impairment or cessation of aqueous outflow from

the anterior chamber of the eye. Aqueous outflow is through the iridocorneal (drainage) angle and in the dog the angle is extended posteriorly into the ciliary body as the ciliary cleft. It is within the ciliary cleft that the trabecular meshwork is found and the canine equivalent of the primate canal of Schlemm, the aqueous plexus, is situated in the scleral tissues which form the outer wall of the cleft. In cases of primary glaucoma, a defect of the iridocorneal angle and the structures associated with the ciliary cleft is responsible for inadequate drainage, leading to an increase of intraocular pressure. The secondary glaucomas are associated with antecedent eye disease such as uveitis, primary lens luxation, trauma and neoplasia.

### Classification

Currently, two types of primary glaucoma may be distinguished, primary closed angle glaucoma (or primary angle closure glaucoma) and primary open-angle glaucoma (see *Primary Glaucoma* — available from [www.bva.co.uk/chs](http://www.bva.co.uk/chs)). The nomenclature has been 'borrowed' from human medicine and, although acceptable, does not describe the situation completely. When these terms are used to describe primary glaucoma in the dog they denote the appearance of the entrance to the ciliary cleft. Thus, in closed angle glaucoma the cleft is closed and in open-angle glaucoma the cleft is open.



**9:** Anterior segment – gross globe – the iris root processes that comprise the pectinate ligament span the entrance to the ciliary cleft. The iris, from which the processes arise, is on the left and the posterior cornea, where the processes insert, is on the right. **10:** Acute closed angle glaucoma. **11:** Welsh Springer Spaniel – chronic closed angle glaucoma with globe enlargement (left eye). **12:** Gonioscopy, Barkan goniolens in situ, a column of saline within the silicone tubing creates a negative pressure to keep the lens in place. **13:** Gonioscopy – Koepple goniolens in situ, coupling gel keeps the lens in place. **14:** Normal drainage angle of a Siberian Husky. The drainage angle is of normal width and is spanned by the pectinate ligament. In this poorly pigmented eye, the white band of the scleral shelf is clearly distinguished. There is great variation in the number, width, pigmentation and distribution of the fibres that comprise the pectinate ligament in different breeds, but the width of the normal drainage angle is not subject to such variation. **15:** Normal drainage angle of a Flat Coated Retriever. The width of the drainage angle is normal and the fibres of the pectinate ligament are clearly defined. This eye is more heavily pigmented than the one pictured on the left and the scleral shelf is obscured by pigment. **16:** Goniodysgenesis in a Flat Coated Retriever. There is extensive pectinate ligament dysplasia and sheets of mesenchymal tissue occlude the majority of the drainage angle. Aqueous drainage is via a limited number of ‘flow holes’. The drainage angle is slightly narrowed and normal pigment obscures the scleral shelf. The eye was normotensive at the time of examination (intraocular pressure of 18 mmHg measured with a Mackay-Marg tonometer), despite the compromised drainage angle. **17:** Welsh Springer Spaniel – goniodysgenesis.

### ● Primary closed angle glaucoma (PCAG)/primary angle closure glaucoma (PACG):

In the normal dog, the ciliary cleft entrance is between 1.5 and 2 mm in width and spanned by a number of iris root processes or fibres, collectively referred to as the pectinate ligament. Dogs which develop primary closed angle glaucoma demonstrate a congenital predisposition, in that the entrance to the ciliary cleft is abnormal and both eyes are affected. The pectinate ligament is dysplastic, or abnormal, and may be seen as sheets of undifferentiated mesenchymal tissue rather than the normal fibrocellular processes. Pectinate ligament abnormality with, or without narrowing of the iridocorneal angle, is referred to as **goniodysgenesis**. To assist owners and breeders and as part of data collection for goniodysgenesis a simple grading system is being piloted to help in the initial assessment of the drainage angle and any changes to the drainage angle over time. A grading scheme will almost certainly replace the ‘Clinically Unaffected’ or ‘Clinically Affected’ classification that was used previously to record the results of examination (see *Primary Glaucoma* — available from [www.bva.co.uk/chs](http://www.bva.co.uk/chs)).

The age at which glaucoma develops tends to vary with breed but, in most, the disease is one of middle age and the presentation can be acute. In addition to raised intraocular pressure the common clinical signs of acute closed angle glaucoma include pain, episcleral congestion, corneal oedema and a dilated non-responsive pupil. The canine drainage angle cannot be viewed directly and a goniolens is needed to assess the pectinate ligament and drainage angle width. The Barkan and Koepple direct goniolenses are used most commonly for assessment of the iridocorneal angle under the Eye Scheme. Gonioscopy

can be used as a method of screening to determine those animals that are predisposed before the disease makes its appearance and affected animals should not be bred from. Routine gonioscopy can be performed at five to six months of age in most breeds and should be repeated, as progression of pectinate ligament abnormality over time has been reported in a number of breeds, including the Flat Coated Retriever, Basset Hound, Dandie Dinmont Terrier and Welsh Springer Spaniel. The Eye Panel Working Party has suggested that gonioscopy is performed at approximately 1, 4 and 7–8 years of age in breeds at risk.

#### Primary closed angle/angle closure glaucoma breeds under Schedule A

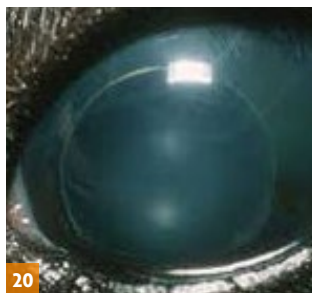
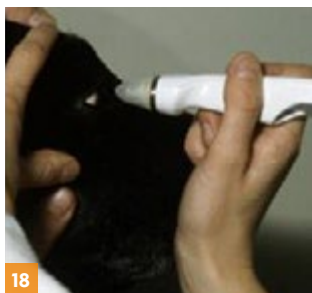Basset Hound  
Dandie Dinmont Terrier  
Japanese Shiba Inu  
Leonberger  
Retriever (Flat Coated)  
Siberian Husky  
Spaniel (American Cocker)  
Spaniel (Cocker)  
Spaniel (English Springer)  
Spaniel (Welsh Springer)  
Spanish Water Dog

The precise modes of inheritance have not been determined for affected breeds, but clear breed and line predisposition indicate a genetically determined cause, albeit with a likely complex mode of inheritance.

### ● Primary open angle glaucoma (POAG):

Primary open angle glaucoma presents both dog breeder and clinician alike with real problems in its early diagnosis, for the usual clinical features of glaucoma are not present. It is silent in onset, with either vision impairment or globe enlargement usually being the first abnormalities reported by the owner. Goniodysgenesis is not a feature of this





**18:** Tonopen in use. **19:** Tonovet in use.  
**20:** Primary open angle glaucoma  
 —the globe is enlarged and  
 secondary lens luxation has occurred.

type of glaucoma and there are no other predisposing features that can be used to forecast the advent of the disease. It is inherited as a simple recessive trait and has been described extensively in the Beagle. In this breed the causal mutation has been identified in the *ADAMTS 10* gene and a DNA based test has been developed. POAG has been reported in other breeds, notably the Norwegian Elkhound and, most recently in the UK, the Petit Basset Griffon Vendeen (PBGV), Basset Hound and Basset Fauve de Bretagne and DNA tests are available.

In the PBGV the earliest clinical presentation is either lens instability (phacodonesis), lens subluxation in a normotensive eye, or actual globe enlargement with possible lens subluxation/luxation and vision impairment. The disease affects most dogs from 3 to 6 years of age, but a later onset is possible. When the intraocular pressure (IOP) increases, variable degrees of episcleral congestion and mild corneal oedema may be seen. The pupil may be partially dilated, but with the passage of time the pupillary light reflex (PLR) is eventually impaired or lost. Signs of ocular pain are subtle and affected dogs are usually lethargic and sleep more; systemic non-steroidal anti-inflammatory drugs benefit such patients. With progression globe enlargement occurs, but it is only in advanced disease that cupping of the optic disc and retinal degeneration characterised by increased tapetal reflectivity and blood vessel attenuation are seen. Lens subluxation may occur even before there is a rise in IOP, but total lens luxation would appear to be unusual unless there is gross globe enlargement. The elevation of IOP is moderate, with pressures between 30 and 40 mmHg being routinely recorded.

In terms of the BVA/KC/ISDS Eye Scheme as applied to POAG, gonioscopy is not necessary, for closure of the iridocorneal angle occurs only in late disease where there is marked globe enlargement, but tonometry can prove helpful where early disease is present. Annual examination in dogs of 3 to 9 years of age is advisable. Lens subluxation is common before and after the rise in IOP, but POAG should not be confused with primary lens luxation (see below).

#### Primary open angle glaucoma breeds under Schedule A

Basset Hound  
 Petit Basset Griffon Vendeen  
 Shar Pei

### Persistent hyperplastic primary vitreous

The embryonic lens is supplied with nutrients by the hyaloid artery (which grows forward from the optic stalk to reach the posterior lens surface at about day 25 of gestation) and the tunica vasculosa lentis (which is formed by day 30 of gestation). Regression of the vascular supply starts at about day 45 of gestation and is complete some two to four weeks after birth. Persistence of these vessels and proliferation of associated mesodermal elements of the tunica vasculosa lentis posterioris produce the main lesion of fibrovascular plaque formation on the posterior lens capsule. This plaque appears as a dense yellow/white opacity with multiple pigment foci attached to the posterior lens capsule. Blood vessels may be visible within the plaque and at its periphery. Other features of persistent hyperplastic primary vitreous include persistent capsulopupillary vessels (iridohyaloid vessels), coloboma of the lens, posterior lenticonus, intralenticular and retrolental haemorrhage, secondary cataract, persistence of the hyaloid artery and Bergmeister's papilla (remnant of the glial sheath around hyaloid vessels on the optic disc), and retinal dysplasia.

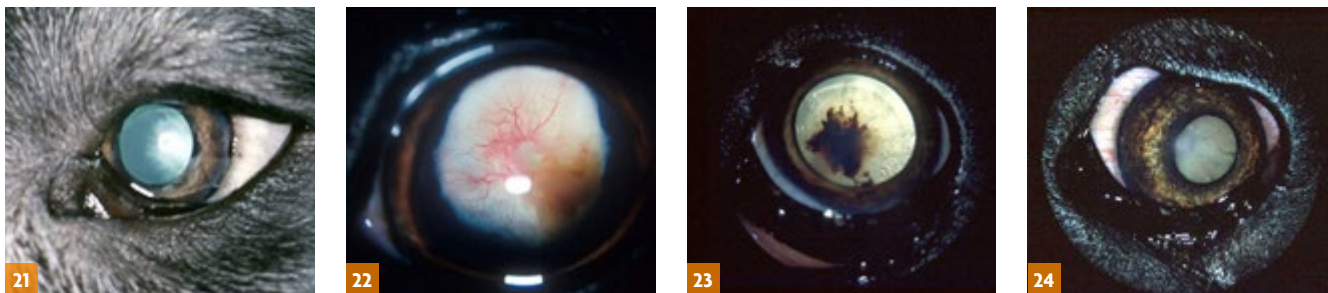
Currently, the Dobermann and Staffordshire Bull Terrier are certified for persistent hyperplastic primary vitreous under the Eye Scheme. The mode of inheritance is complex and to date no mutations have been identified that play a role in the development of this disease, although the genetic data available suggest an autosomal dominant gene with variable or incomplete penetrance.

### Significance

Severe lesions cause marked visual loss or blindness. Yellow/brown focal dots on the posterior lens capsule, the mildest form of PHPV, have no discernible effect on vision. Small areas of retrolental plaque formation may spare the lens periphery and allow adequate vision. More extensive plaques and cataract, or other lens abnormalities, usually cause severe visual impairment or blindness. The Staffordshire Bull Terrier suffers less from the posterior lens capsule deformities, but has more widespread retinal folds and rosettes than the Dobermann. The condition is not common in either breed in the UK, but represents a serious congenital inherited problem in some affected dogs. Surgical treatment of those cases with visual problems is fraught with difficulty and there is a high risk of postoperative complications.

#### Persistent hyperplastic primary vitreous breeds under Schedule A

Dobermann  
 Staffordshire Bull Terrier



**21:** Persistent hyperplastic primary vitreous in a Doberman. The white opacity visible through the pupil involves the vitreous and posterior lens capsule. **22:** Persistent hyperplastic primary vitreous with intralenticular haemorrhage ventrolaterally. The intralenticular haemorrhage progressed to involve the whole lens. **23:** Persistent hyperplastic primary vitreous. In this dog, the hyaloid vessel has remained patent and there is haemorrhage into the lens. Note the numerous vacuoles within the lens cortex, which are indicative of progressive cataract formation. **24:** The same eye as that pictured in 23 some months later after cataract formation.

## Retinal dysplasia

The term retinal dysplasia embraces a number of congenital/neonatal conditions resulting from disorderly proliferation and atypical differentiation of the retina during embryonic life. In addition to genetically determined hereditary retinal dysplasia, a wide variety of extraneous insults (for example, infectious agents such as canine herpes virus and irradiation) to the developing retina may cause acquired, non-inherited, retinal dysplasia. Defective retinal development results in extremely varied clinical and microscopic appearances so that, for example, folds, ridges, rosettes, geographic abnormalities and localised detachments are all possible manifestations of multifocal retinal dysplasia, whereas total retinal dysplasia is most commonly associated with non-attachment or complete detachment of the retina.

### Classification

#### ● Multifocal retinal dysplasia:

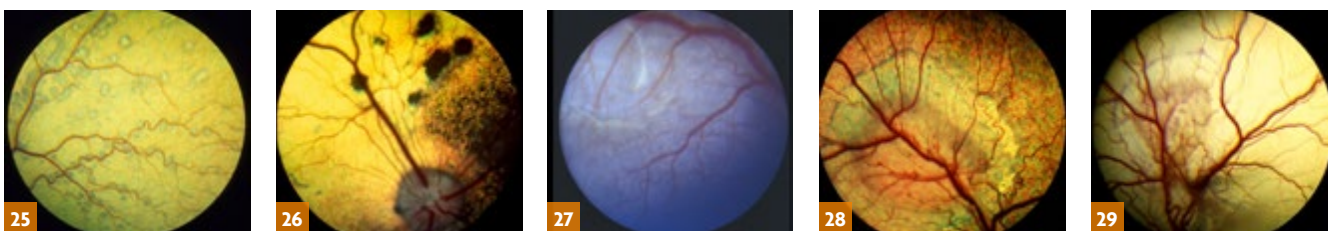
Linear folding of the sensory retina and the formation of rosettes composed of variable numbers of neuronal retinal cells are the histological characteristics of multifocal retinal dysplasia. Typically, the lesions range from vermiform grey streaks, dots and circles to multiple focal sites of tapetal hyperreflectivity, which may or may not be associated with hypertrophy of the retinal pigment epithelium. Irregularly shaped (geographic) areas of retinal dysplasia may also be encountered. In most cases, the lesions are most obvious in the tapetal fundus dorsal to the optic disc. In the English Springer Spaniel, dysplastic changes occur in the developing sensory retina at 45 to 50 days of gestation. The other breeds at present certified under the Eye Scheme for

multifocal retinal dysplasia are the Cavalier King Charles Spaniel, Hungarian Puli, Rottweiler, Golden Retriever and American Cocker Spaniel.

Litter screening is useful, although subtle changes are not always clearly defined. In older animals remodelling of some or all multifocal lesions may result in them becoming less obvious, even disappearing, over time. This does not appear to be the case with the geographic form.

#### ● Total retinal dysplasia:

Somewhat more complex, this form of retinal dysplasia is associated with non-attachment or complete detachment of the retina. Non-attachment may result from apparent failure of contact of the inner (retinal) and outer (retinal pigment epithelial) layers of the optic cup during embryogenesis; other ocular abnormalities, such as microphthalmos and nystagmus, are often present in these cases. The Bedlington Terrier, Labrador Retriever and Sealyham Terrier are certified for total retinal dysplasia under the Eye Scheme, although total retinal dysplasia has been recorded in other breeds, including the Yorkshire Terrier and Samoyed. In the Bedlington Terrier most affected dogs have an infundibular retinal detachment. Puppies are blind from birth and may present with leukocoria, a white pupil, because the retina is immediately behind the posterior lens capsule. Retinal neovascularisation may result in intraocular haemorrhage. In the Sealyham Terrier a total detachment of the retina is similarly present and microphthalmos and nystagmus are common. Two forms of total retinal dysplasia are recognised as inherited in the Labrador Retriever. In one form associated with complete



**25:** Golden Retriever—multifocal retinal dysplasia. **26:** Multifocal retinal dysplasia in an English Springer Spaniel. Some of the larger focal lesions with pigmented centres to the right of the dorsal primary retinal vessels resemble inactive chorioretinopathy, but there are also classical rosettes and vermiform lesions to the left of the vessels. **27:** Cavalier King Charles Spaniel puppy—geographic retinal dysplasia. **28:** Cavalier King Charles Spaniel—geographic retinal dysplasia. **29:** Golden Retriever—geographic retinal dysplasia and haemorrhage.

detachment, the defect seems to result from an inability of the developing retina to match the rapid growth of the choroid and sclera. The resulting detachment leads to degeneration of the neurosensory retina because of ischaemic anoxia and such animals are blind.

Other ocular defects, such as microphthalmos, nystagmus and cataract, may be present. The second form of total retinal dysplasia, which has not been reported in the UK, is ocular-skeletal dysplasia associated with severe ocular defects and short-limbed dwarfism. In addition to the Labrador Retriever (dwarfism with retinal dysplasia type 1—DRD1) it has also been reported in the Samoyed (dwarfism with retinal dysplasia type 2—DRD2). This phenotype is inherited as an autosomal recessive in both breeds and mutations have been identified; a 1-base insertional mutation in exon 1 of COL9A3 in the Labrador Retriever and a 1,267-bp deletion mutation in the 5' end of COL9A2 in the Samoyed.

## Significance

A simple autosomal recessive gene is responsible for retinal dysplasia in most of the breeds studied. Diagnosis is complicated by the fact that retinal dysplasia may be the result of both genetic and non-genetic influences, the ophthalmoscopic changes may be more difficult to detect in the developing eye (ie, in puppies of less than six months of age) and there is not always a clear distinction between the various ocular manifestations of the multifocal and total types. To add yet further complexity, remodelling of dysplastic lesions may occur over time.

While many dogs with multifocal retinal dysplasia will have no obvious visual defect, some are severely visually impaired, as are all dogs affected with total retinal dysplasia. There is, therefore, no question of not examining 'at risk' breeds under the Eye Scheme.

### Multifocal retinal dysplasia/ Total retinal dysplasia breeds under Schedule A

#### Certified – Schedule A (TRD)

Bedlington Terrier  
Sealyham Terrier

#### Certified – Schedule A (MRD)

Cavalier King Charles Spaniel  
Hungarian Puli  
Retriever (Golden)  
Rottweiler  
Spaniel (American Cocker)  
Spaniel (English Springer)

#### Certified – Schedule A

(TRD and MRD)  
Retriever (Labrador)


TRD Total retinal dysplasia, MRD  
Multifocal retinal dysplasia

## Collie eye anomaly (CEA)

The prevalence of Collie eye anomaly in the UK is high, in excess of 60% in the Rough Collie, Smooth Collie and Shetland Sheepdog, with the Lancashire Heeler and Border Collie much less affected. The condition has a worldwide distribution and ocular lesions of identical ophthalmoscopic appearance have been described in a number of other collie and non-collie breeds, such as the Bearded Collie and Australian Shepherd. CEA is a complex disorder affecting retinal, choroidal and scleral development. The classical lesion is of choroidal hypoplasia in the lateral or dorsolateral region of the fundus near the optic disc. In some animals the hypoplasia may be more extensive and it is not uncommon for the two eyes to be dissimilar. The lesion is apparent as a 'pale patch' and is due to a localised lack of some, or all, retinal and choroidal pigment and tapetum. The choroidal vessels in the affected region are also abnormal, usually in size, number and disposition. In merle dogs, with little pigmentation in the fundus and no tapetum, choroidal hypoplasia will be less obvious and the appearance of the choroidal vessels then becomes the important diagnostic feature. In addition to choroidal hypoplasia, colobomas and staphylomas of the optic nerve head and/or adjacent tissues may be part of the extended phenotype and can sometimes be the only visible abnormality. It has been suggested that adult dogs in this category may be examples of so-called 'go normals'. The term 'go normal' has been applied to cases where post natal development (pigmentation and tapetal development) obscures the choroidal hypoplasia which is the key diagnostic feature, so that adult dogs have a fundus of 'normal' appearance; however, this description might be regarded as inappropriate because such dogs are genotypically affected. The phenomenon is common enough to call into question the relevance of examining dogs as adults rather than as puppies. Data on Collie eye anomaly in the Rough Collie in Norway, for example, has indicated that the diagnosis of the condition in a group of dogs of more than three months of age was almost half that for a group of puppies of seven weeks to three months of age. Furthermore, when puppies which had been diagnosed as having Collie eye anomaly with mild choroidal hypoplasia at between seven weeks and three months of age were re-examined at about one year of age, 68 per cent had a fundus of normal appearance.

### Collie eye anomaly breeds under Schedule A

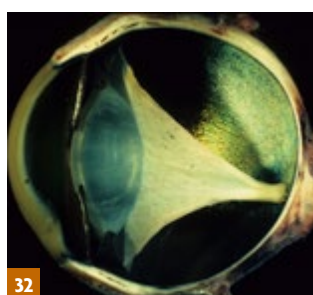
Border Collie  
Collie (Rough)  
Collie (Smooth)  
Lancashire Heeler  
Shetland Sheepdog



30



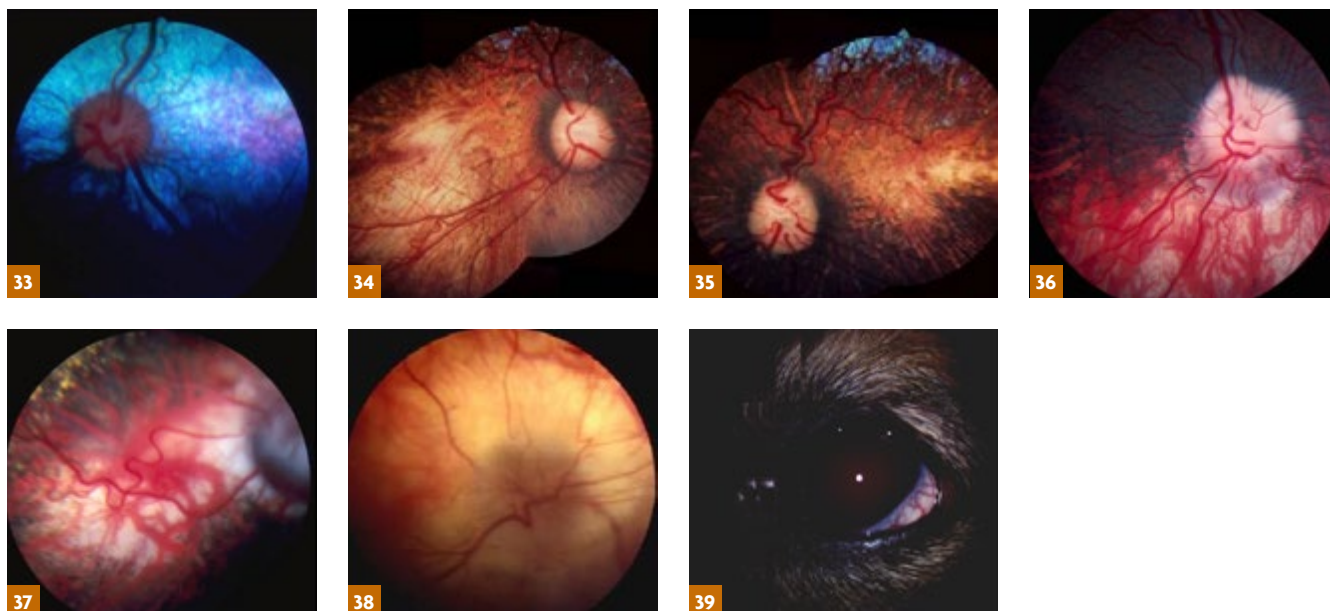31



32

**30:** Total retinal dysplasia in a Labrador Retriever puppy. **31:** Close-up of the eye of this puppy. The retina can be visualised behind the lens. **32:** Gross globe—total retinal dysplasia with infundibular retinal detachment.





**33:** Collie eye anomaly in a five-week-old Border Collie puppy. A region of chorioretinal hypoplasia (pale patch) is obvious lateral and slightly dorsal to the optic nerve head. **34:** Border Collie—Collie eye anomaly right eye. **35:** Border Collie—Collie eye anomaly left eye. **36:** Collie eye anomaly in an adult Rough Collie. The most striking feature is the peripapillary coloboma ventral to the optic nerve head. **37:** Collie eye anomaly in an adult Border Collie. This image is dominated by a large colobomatous defect to the right of the picture and there is also extensive chorioretinal hypoplasia lateral to the coloboma. **38:** Rough Collie—Collie eye anomaly with retinal detachment. **39:** Shetland Sheepdog — Collie eye anomaly with intraocular haemorrhage.

Complications such as retinal detachment and intraocular haemorrhage are fortunately rare; thus, the majority of dogs with Collie eye anomaly show no apparent visual defect.

Tortuosity of the retinal vessels and retinal folds, the latter usually in the form of vermiform streaks, are not now regarded as part of the syndrome, but may relate to the smallness of the eye.

### Significance

A variety of fundamental issues combine to make this a difficult clinical diagnosis on occasions, however, it is worth emphasising that Collie eye anomaly is a congenital condition which can be diagnosed as soon as eye examination is possible (ie at five to six weeks of age), and that it is diagnosed clinically with greatest accuracy in such young dogs. In aiming to eliminate CEA from a breed, litter screening, combined with DNA testing is the best approach. Advances in canine genetics have shown that the primary CEA mutation has arisen as a single disease allele in a common ancestor of herding breeds and that all affected dogs share a homozygous deletion of 7.8 kb in the *NHEJ1* gene. The availability of a DNA test has proved of great value in devising comprehensive breeding strategies.

### Hereditary cataract (HC)

The canine lens is an asymmetrical, transparent, biconvex sphere, with the more convex aspect posteriorly. The adult lens consists of a central nucleus surrounded by cortical lens fibres and the nucleus itself is divisible into various regions according to age: the oldest, central, portion of the lens is the embryonic nucleus; surrounding that is the foetal nucleus; and the outermost portion is the adult nucleus. The whole lens is contained within an acellular capsule (the anterior capsule is thicker than the posterior capsule). A single layer of epithelial cells lies immediately beneath the anterior capsule and it is these cells which form the germinal

cell layer that produces new lens fibres throughout life. The epithelial cells migrate peripherally and elongate at the equator (circumference) of the lens. Each fibre extends anteriorly and posteriorly to meet fibres to the front and rear to form the suture lines. The suture lines form an upright 'Y' anteriorly and an inverted 'Y' posteriorly.

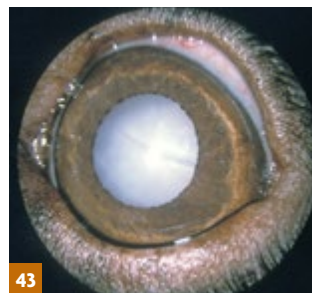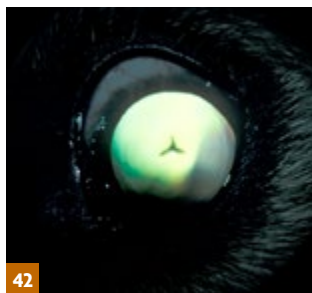
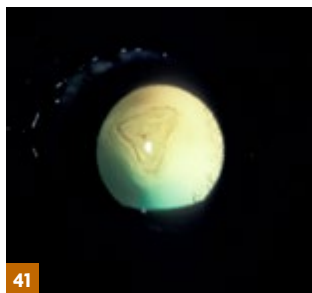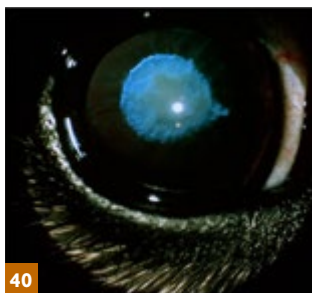
Cataract is defined as any opacity of the lens or its capsule. There are many reasons for cataract formation—cataracts may be congenital, due to *in utero* insult; traumatic, as a result of blunt or penetrating injury to the eye; metabolic, as a consequence of, for example, diabetes mellitus; toxic, caused by some drugs; nutritional, produced by inappropriate diets; or a complication of other primary ocular diseases such as uveitis and neoplasia. Cataracts may also form in dogs with generalised progressive retinal atrophy.

Additionally, primary inherited cataracts have been reported in a number of breeds and it is these with which the Eye Scheme is concerned. Fortunately, the age of onset, appearance and evolution of the cataracts which are certified under Schedule A of the Eye Scheme are usually quite specific within the affected breeds, enabling inherited cataracts to be distinguished from

#### Hereditary cataract breeds under Schedule A

Alaskan Malamute  
Australian Shepherd  
Belgian Shepherd Dog  
Bichon Frise  
Boston Terrier\*  
Cavalier King Charles Spaniel  
German Shepherd Dog  
Giant Schnauzer  
Irish Red and White Setter  
Large Munsterlander  
Leonberger  
Miniature Schnauzer\*  
Norwegian Buhund  
Old English Sheepdog  
Poodle (Standard)  
Retriever (Chesapeake Bay)  
Retriever (Golden)  
Retriever (Labrador)  
Siberian Husky  
Spaniel (American Cocker)  
Spaniel (Welsh Springer)  
Staffordshire Bull Terrier\*

\*More than one type of hereditary cataract can occur within an individual breed



**40:** Congenital hereditary cataract in a Miniature Schnauzer. The nuclear portion of the lens is affected and there is a pyramid-shaped extension medially. Picture: Dr Keith Barnett. **41:** Hereditary cataract in a Norwegian Buhund. There is an obvious opacity, located posteriorly, involving the posterior pole and posterior suture lines. In this breed pulverulent nuclear cataracts have also been reported as inherited (see Figure 85). **42:** Hereditary cataract in a Golden Retriever. The characteristic Y-shaped cataract is located in a posterior polar subcapsular position. **43:** Total hereditary cataract in a Labrador Retriever.

other non-inherited types of cataract. At present, congenital cataract in the Miniature Schnauzer is the only congenital inherited cataract included in the Eye Scheme; the remainder are all non-congenital types and, as some of them have a variable age of onset, it is important to examine dogs of over eight years of age to ensure that animals that have been used for breeding remain free of inherited cataract.

### Significance

Quite apart from the undesirable perpetuation of abnormality within breeding lines, a proportion of inherited cataracts progress to produce visual impairment and blindness. The only treatment for cataract is surgical and, although modern techniques give good results, the procedure is expensive.

### Primary lens luxation (PLL)

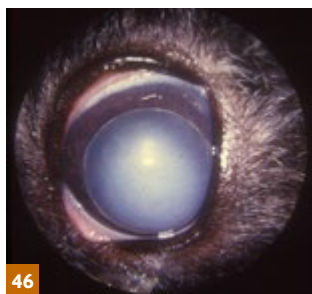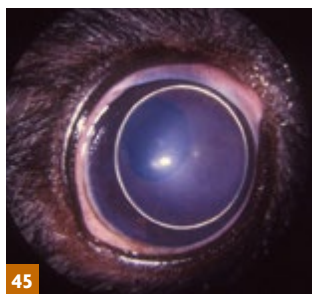
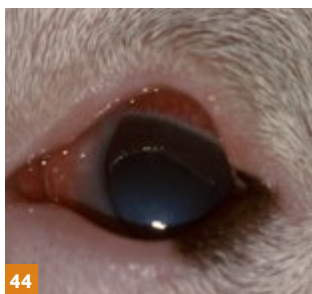
Primary lens luxation is a condition in which an inherent defect in the zonule (the suspensory ligament of the lens) leads to partial or complete dislocation of the lens at approximately four to five years of age; clinical signs are not usually observed before three years of age or later than seven years of age. It is a common cause of secondary glaucoma and, as such, an important disease to recognise because of the potential for pain and visual loss. Primary lens luxation is recognised as a familial problem in certain of the terrier breeds (Miniature Bull Terrier, Smooth Fox Terrier, Wire Fox Terrier, Parson Jack Russell Terrier and Sealyham Terrier), the Tibetan Terrier (which is not a true terrier breed), the Lancashire Heeler and the Border Collie. A single nucleotide substitution in the *ADAMTS17* gene has been shown to be the cause of PLL in 17 breeds (the Australian Cattle Dog, the Chinese Crested Dog, the Jagdterrier (also known as

the German Hunt Terrier), the Lancashire Heeler, the Miniature Bull Terrier, the Jack Russell Terrier, the Parson Russell Terrier, the Patterdale Terrier, the Rat Terrier, the Sealyham Terrier, the Tenterfield Terrier, the Tibetan Terrier, the Toy Fox Terrier, the Volpino Italiano, the Welsh Terrier, the Wire-haired Fox Terrier and the Yorkshire Terrier). This mutation has been excluded from involvement in the Border Collie and the Shar Pei, indicating other mutations are the cause in these breeds.

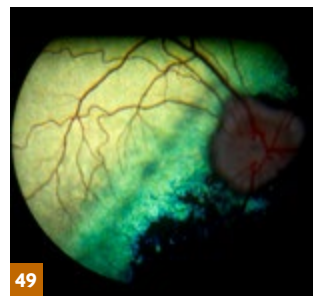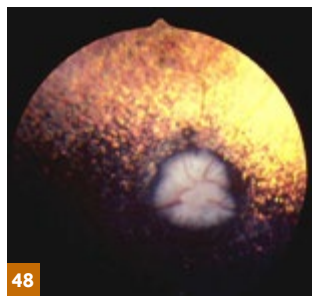
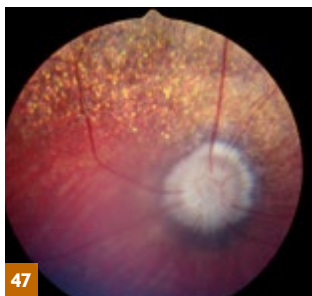
#### Primary lens luxation breeds under Schedule A

Border Collie  
Bull Terrier (Miniature)  
Fox Terrier (Smooth)  
Fox Terrier (Wire)  
Lancashire Heeler  
Parson Russell Terrier  
Sealyham Terrier  
Tibetan Terrier

The condition is essentially bilateral, but almost invariably presents as a uniocular condition, as one eye may be affected weeks or months in advance of the other. Observant owners may notice a change in the appearance of the affected eye which correlates with the lens moving out of its normal position. When the lens moves anteriorly, secondary glaucoma develops rapidly and pain, blepharospasm, photophobia and lacrimation, an increase in intraocular pressure, together with a widely dilated non-responsive pupil, visual loss and episcleral and conjunctival congestion, are the most obvious clinical features. With posterior lens luxation, secondary glaucoma is less likely, although most lenses will move forward at some stage. Careful observation will reveal the displaced lens (usually the lens equator is highlighted by the penlight used for examination), in addition vitreal prolapse and instability of the lens may also be apparent (phacodonesis). In addition, the iris trembles slightly with head and eye movement (iridodonesis) because it has lost the support of the lens.



**44:** Primary lens luxation in a Miniature Bull Terrier. The changes were acute, and the eye painful and red (episcleral congestion), indicative of glaucoma (the intraocular pressure measured with a Mackay-Marg tonometer was 60 mmHg). The other eye was normotensive (intraocular pressure 22 mmHg). The lens has luxated anteriorly and an area of corneal oedema is apparent as a result of endothelial damage from contact with the lens. The lens equator is highlighted by illumination from a penlight. **45:** Tibetan Terrier – primary lens luxation (anterior). **46:** Tibetan Terrier – primary lens luxation, the anteriorly dislocated lens has developed cataract.



**47:** Progressive retinal atrophy in a Cocker Spaniel. Attenuation of the retinal vessels and pallor of the optic nerve head are the most obvious features as tapetal islets (a normal variant) do not produce the striking hyperreflectivity seen with a more extensive tapetum. Vision was seriously compromised in this dog. **48:** Progressive retinal atrophy in a Miniature Poodle. Tapetal hyperreflectivity is obvious, the optic nerve head is pale and the retinal vessels scarcely visible. The animal was almost totally blind. **49:** Progressive retinal atrophy in a Cocker Spaniel. An abnormal zone is apparent slightly dorsal to the optic nerve head. The zone appears dull or hyperreflective depending on the direction of the light source. The retinal vessels are marginally narrower than usual and the animal's vision was apparently unaffected.

## Significance

Primary lens luxation is an inherited problem which can cause persistent pain and blindness without prompt surgical intervention. Affected dogs should not be bred from and the 'at risk' breeds that are to be used for breeding should be examined under the Eye Scheme.

## Progressive retinal atrophy (PRA)

Progressive retinal atrophy (PRA), is a generic term for a range of genetically heterogeneous inherited retinal diseases affecting many breeds of dog. PRA involves the retinal photoreceptors and two major types are recognised—developmental (dystrophies) and degenerative. The developmental disorders are of early onset and involve the rod or cone photoreceptors, or both, the loss of photoreceptors and rate of progression is usually rapid as the affected photoreceptors fail to differentiate normally. The degenerative disorders by contrast usually involve photoreceptors that have differentiated normally and the age of onset is later and progression slower. For example, in a breed such as the Irish Setter, with rod/cone dysplasia, the photoreceptors are abnormally formed and begin to degenerate before they are mature. The disease, therefore, affects these dogs at a relatively young age. The age of onset is later in, for example, the rod/cone degeneration of the Miniature and Toy Poodle, as the photoreceptors degenerate after reaching maturity.

The clinical findings in PRA are strikingly similar whatever the underlying pathogenesis. Owners usually notice a loss of night vision, especially when the dog is in unfamiliar surroundings. The condition progresses to produce a loss of vision under all lighting conditions and there is a poor pupillary light reflex with dilated pupils. In time, secondary cataract formation is common. Ophthalmoscopic examination indicates a generalised, bilaterally symmetrical increase in tapetal reflectivity (a consequence of retinal atrophy). There is attenuation (narrowing) of the retinal vessels, especially the small peripapillary arterioles, which may become barely visible ('ghost vessels') or invisible on ophthalmoscopy. In dogs with a poorly developed tapetum or an atapetal fundus, the attenuation of the retinal vessels may be the only obvious ophthalmoscopic sign of early progressive retinal atrophy, necessitating careful observation. Later in the course of the disease the optic disc becomes paler due to atrophy of its capillaries and nerve fibres. The non-tapetal fundus also shows extensive areas of depigmentation as the condition progresses.

Cataracts, which form late on in the condition, may manifest as opacities in the posterior cortex, or as radial opacities, before progressing to total cataract.

In those disorders in which the cones or rods are preferentially affected (for example, cone degeneration in the Alaskan Malamute, or rod dysplasia in the Norwegian Elkhound) the visual defect will reflect the type of photoreceptor involved—tending to day blindness when cone photoreceptors are abnormal and night blindness when rod photoreceptors are abnormal.

## Significance

Most types of PRA are autosomal recessive traits but, less commonly, autosomal dominant and X-linked types of PRA have also been reported.

There is currently no effective treatment for these conditions, so it is DNA testing that underpins efforts to eliminate PRA in many breeds, including a form of PRA, breed specific retinopathy, in the Swedish Vallhund.

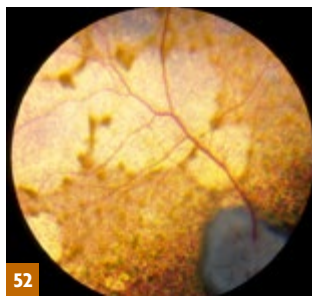
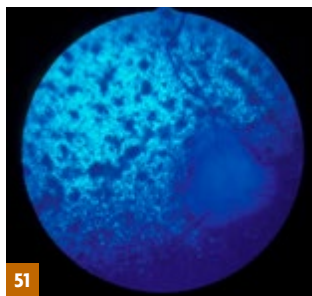
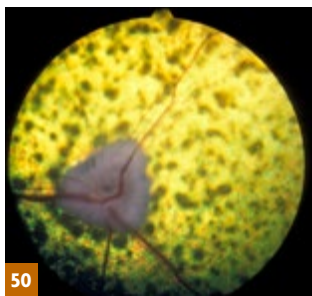
## Retinal pigment epithelial dystrophy (RPED) / central progressive retinal atrophy (CPRA)

Retinal pigment epithelial dystrophy, for many years referred to as Central Progressive Retinal Atrophy (CPRA), is a disease of the retinal pigment epithelium cells. The breeds at present certified under the Eye Scheme are the Border Collie, Briard, Rough Collie, Smooth Collie, Golden Retriever, Labrador Retriever, Shetland Sheepdog, Cocker Spaniel, English Springer Spaniel and Cardigan Welsh Corgi. Ophthalmoscopic signs may be detected on occasion in dogs of just over 12 months of age, but it is more usual to make the diagnosis from about 18 months of age onwards. Electroretinography is not of value in early diagnosis.

### Progressive retinal atrophy breeds under Schedule A

Australian Cattle Dog  
Collie (Rough)  
Dachshund (Miniature Long-Haired)  
Finnish Lapphund  
Glen of Imaal Terrier  
Gordon Setter  
Irish Setter  
Irish Wolfhound  
Lhasa Apso  
Miniature Schnauzer  
Norwegian Elkhound  
Poodle (Miniature)  
Poodle (Toy)  
Retriever (Chesapeake Bay)  
Retriever (Golden)  
Retriever (Labrador)  
Retriever (Nova Scotia Duck Tolling)  
Spaniel (American Cocker)  
Spaniel (Cocker)  
Spaniel (English Springer)  
Swedish Vallhund  
Tibetan Terrier  
Welsh Corgi (Cardigan)





**50:** Retinal pigment epithelial dystrophy in a Cocker Spaniel. At this relatively early stage, multiple focal accumulations of lipopigment are the most obvious feature, together with some vascular attenuation and a slightly pale optic nerve head. **51:** Cocker Spaniel – retinal pigment epithelial dystrophy, other eye of the same dog (as 50) photographed in blue light. **52:** Retinal pigment epithelial dystrophy in another Cocker Spaniel at a later stage of disease. The lipopigment has migrated to produce a more cobweb-like appearance.

The disease is caused by the inability of the retinal pigment epithelial cells to degrade spent photoreceptor metabolites, with the resultant accumulation of lipopigment within the retinal pigment epithelium. There are focal concentrations of lipopigment-laden cells which migrate into the true retinal layers. Degeneration of the photoreceptors (rods and cones) and retinal atrophy are secondary to the lipopigment accumulation and retinal pigment epithelial cell malfunction.

In dogs of working breeds, the owner may notice an inability to work in bright light, while vision in dim light may be adequate until the disease is advanced. In pet dogs, suspect vision may not be noticed as early. Affected dogs may exhibit a central visual defect, but the pupillary light response is often reasonable and complete blindness is unusual.

Ophthalmoscopic examination of early cases indicates light brown foci in the tapetal fundus. These become more numerous and eventually coalesce into larger areas of lipopigment with hyperreflective areas between. In advanced cases the pigment becomes less obvious as hyperreflectivity increases. The retinal blood vessels may become attenuated late in the disease, but the appearance of the non-tapetal fundus and optic disc alters little. Both eyes are affected.

#### Retinal pigment epithelial dystrophy (RPED/CPRA) breeds under Schedule A

Border Collie  
Briard  
Collie (Rough)  
Collie (Smooth)  
Retriever (Golden)  
Retriever (Labrador)  
Shetland Sheepdog  
Spaniel (Cocker)  
Spaniel (English Springer)  
Welsh Corgi (Cardigan)

The Briard is of interest in that a defect in retinal polyunsaturated fatty acid metabolism may underlie a form of congenital night blindness in which the appearance of the ocular fundus is initially normal, but by two to three years of age subtle hyper-reflectivity of the tapetal fundus is apparent, together with sparse greyish spots, which increase in number as the disease progresses, accompanied by moderate attenuation of the retinal vessels.

#### Significance

Unlike generalised progressive retinal atrophy, retinal pigment epithelial dystrophy rarely causes blindness and secondary cataract formation is also unusual. However, when the

disease develops in a working dog, the effects are predictably serious. The inheritance of the disease appears complex and environmental factors (for example, poor quality diet) may influence the phenotypic expression. It is prudent to advise against breeding from affected dogs and their relatives, although the mode of inheritance has not been confirmed.

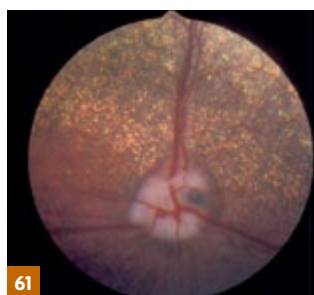
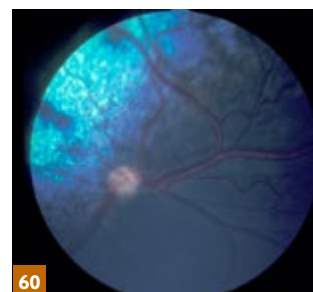
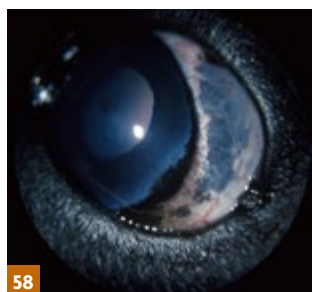
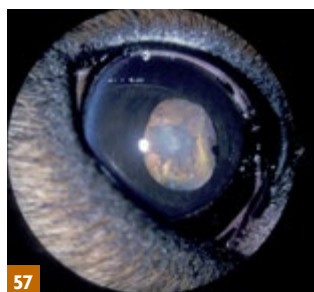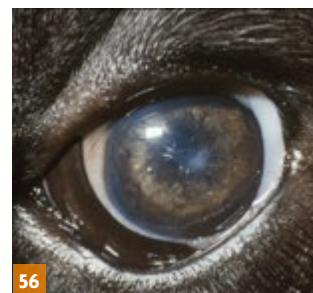
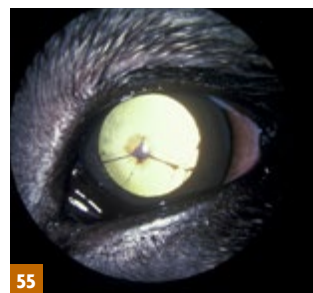
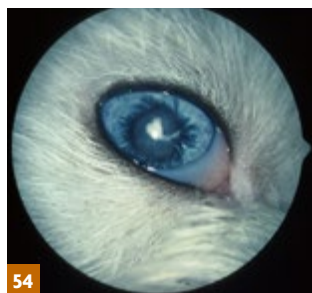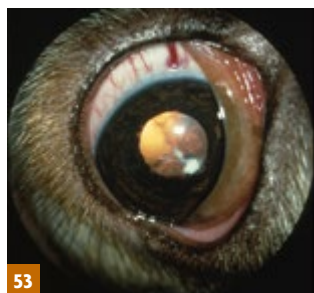
## Examples of conditions recorded in comments section

Written descriptive comments can be made on both the Eye Examination Certificate and Litter Screening Eye Examination Certificate providing further information on any Schedule A inherited eye diseases identified and as a means of recording other conditions identified in the course of the clinical examination. Examples include:

- Breed-related eye diseases which may be inherited, currently designated as ‘Under Investigation’ (Schedule B);
- Other breed-related anomalies and abnormalities of the eye and adnexa which may be inherited;
- Acquired ocular abnormalities (for example, post-traumatic damage, neoplasia, active/inactive inflammation);
- Ocular changes indicative of systemic disease.

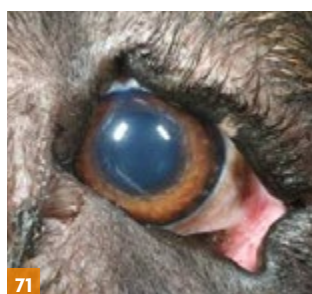
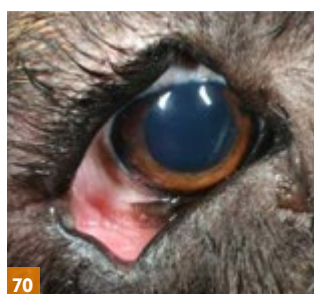
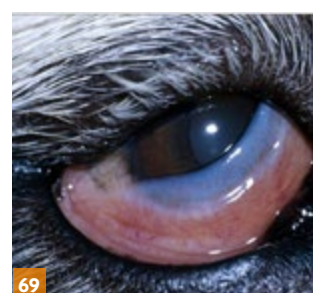

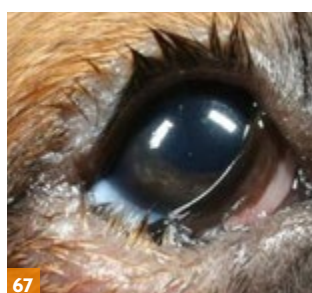
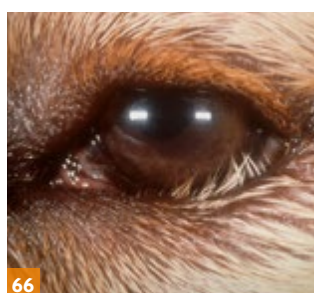
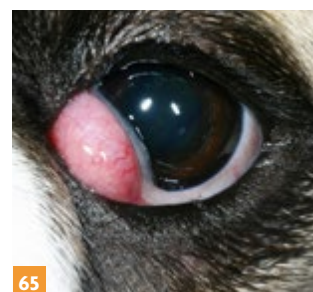


Such observations are important if the abnormalities identified have welfare implications, particularly so if they might be passed on to subsequent generations. Examples of relevant breed-related abnormalities with a genetic component include ocular problems associated with excessive amounts of loose skin, imperfect eyelid anatomy (for example, entropion, ectropion and combinations of entropion and ectropion) and ocular-related disease associated with brachycephaly (for example, lagophthalmos and corneal damage).

## Breed-related ocular conditions that may be inherited, currently listed under Schedule B



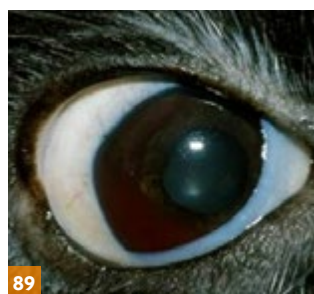
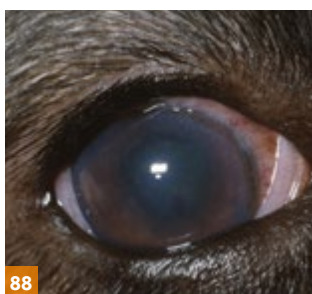
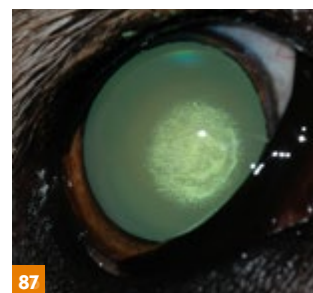
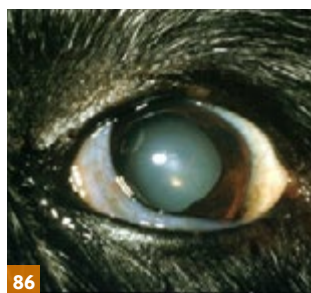
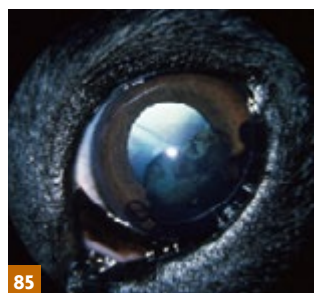
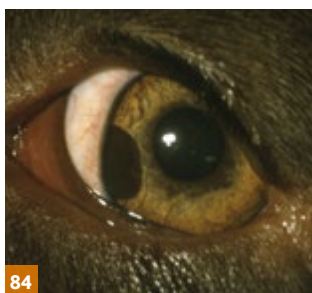
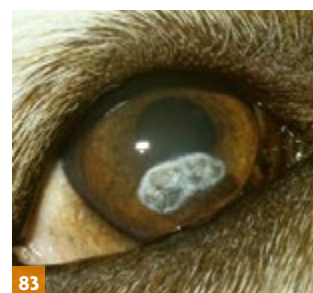
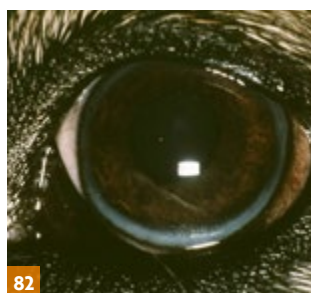
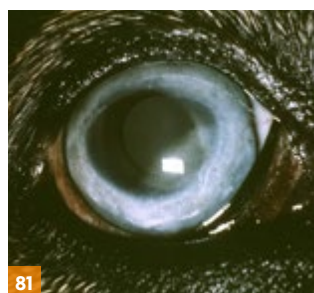
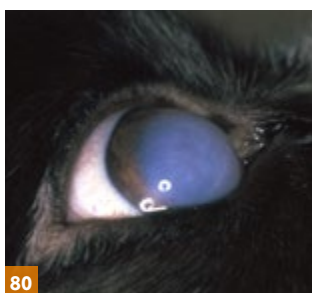
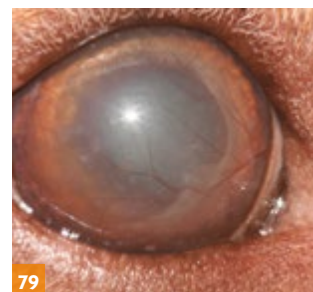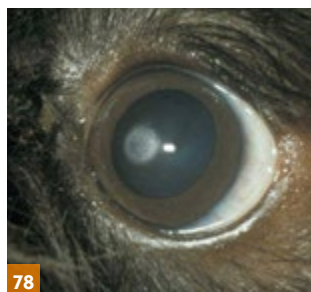

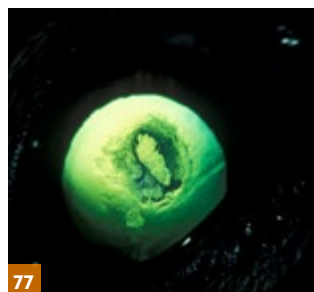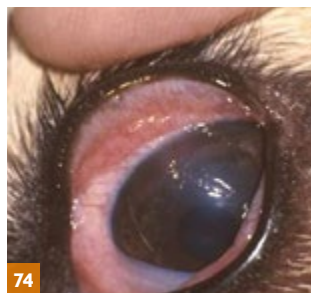
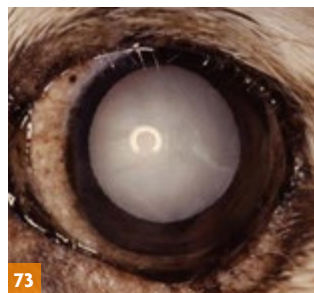
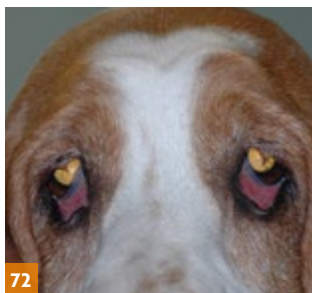
**53:** Multiocular defects in a Cocker Spaniel. The eye is microphthalmic and a congenital cataract is present. Retinal dysplasia was an additional finding. **54:** Multiocular defects in an Old English Sheepdog. The eye is microphthalmic and both a congenital cataract and persistent papillary membrane remnants are present. **55:** Persistent pupillary membrane. Most of the remnants arise from the iris collarette and extend anteriorly to the cornea where a discrete opacity is present at the point of contact. **56:** Persistent pupillary membrane. Most of the remnants arise from the iris collarette and extend posteriorly to the lens. Note the associated pigment deposition on the anterior lens capsule. **57:** Congenital hereditary cataract and uveitis in a Golden Retriever. Note the darkly pigmented iris cyst in the pupillary aperture medially. **58:** Ocular melanosis (abnormal pigment deposition) in a Labrador Retriever. **59:** Ocular melanosis (abnormal pigment deposition) in a Cairn Terrier – secondary glaucoma has resulted in an enlarged globe. **60:** Optic nerve hypoplasia in a Miniature Poodle. **61:** Papillary coloboma.

## Other breed-related ocular conditions of known and potential inheritance



**62:** Pug – brachycephaly is associated with respiratory and ocular problems. The common anatomical-related problems that render the eye more susceptible to mechanical insult can be summarised as a prominent eye, macropalpebral fissure and lagophthalmos. Chronic pigmentary keratitis is also present in this dog. **63:** Shar Pei – multiple skin problems (including poor eyelid conformation and entropion) associated with hereditary cutaneous hyaluronosis. **64:** Neapolitan mastiff puppy – excessive skin folds and poor eyelid conformation. **65:** Bulldog – prolapsed nictitans gland, sparse distichia, subtle medial lower lid entropion. **66:** Golden Retriever – lower eyelid entropion. **67:** Boerbel puppy – severe bilateral entropion (right). **68:** Boerbel puppy – severe bilateral entropion (left). **69:** Great Dane – lower eyelid ectropion. **70:** St Bernard – 'diamond eye' – combined entropion and ectropion (right). **71:** St Bernard – 'diamond eye' – combined entropion and ectropion (left).



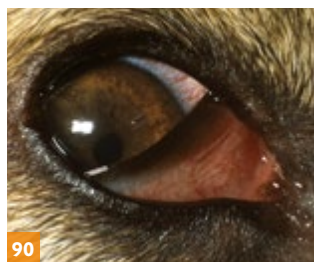


**72:** Basset Hound – combined entropion and ectropion and trichiasis.

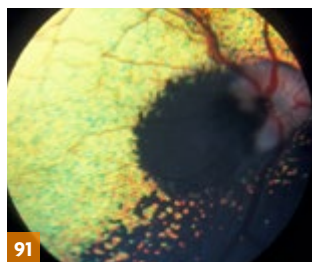
**73:** American Cocker Spaniel – distichiasis and cataract. **74:** Shetland Sheepdog – ectopic cilia and corneal ulcer. **75:** Cocker Spaniel – epiphora (right) associated with lower lacrimal punctal aplasia (imperforate punctum). **76:** West Highland White Terrier – keratoconjunctivitis sicca. **77:** Boxer – epithelial basement membrane dystrophy. **78:** Cavalier King Charles Spaniel – crystalline corneal dystrophy (Schnyder-like corneal dystrophy). **79:** Labrador Retriever – macular corneal dystrophy. Picture: Animal Health Trust. **80:** English Springer Spaniel – endothelial dystrophy. **81:** German Shepherd Dog – corneal arcus (arcus lipoides corneae) secondary to hypothyroidism (right eye). **82:** German Shepherd Dog – corneal arcus (arcus lipoides corneae) secondary to hypothyroidism (left eye). **83:** Golden Retriever – lipid keratopathy. **84:** Labrador Retriever – iris melanoma. **85:** Multiple iris cysts and early, non-inherited, cataract in an aged Labrador Retriever. **86:** Senile nuclear sclerosis in an aged Border Collie. **87:** Alaskan Malamute – pulverulent nuclear cataract. Opacities involving the lens or its capsule are frequently observed as incidental findings under the Eye Scheme and there are many causes, of which possible inheritance is just one. **88:** Akita – uveodermatological syndrome. **89:** Cocker Spaniel – immune-mediated thrombocytopenia.



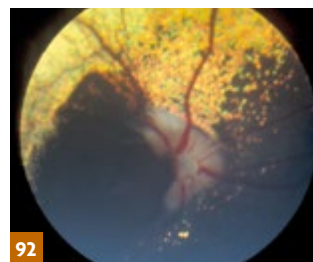
## Examples of other conditions observed as part of examination under the Eye Scheme



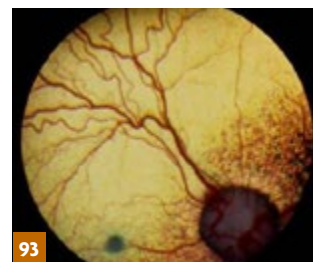
90



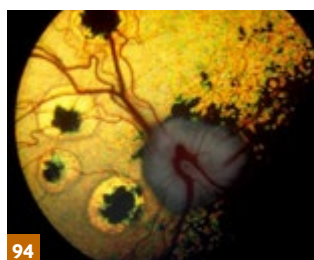
91



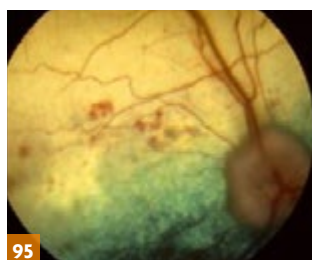
92



93



94



95

**90:** Corneal foreign body (thorn). **91:** Briard – nevus identified at examination under the Eye Scheme and then followed over several years. **92:** Briard – nevus some two years later. **93:** Focal granuloma (ocular larva migrans). **94:** Border Collie – inactive focal chorioretinopathy lesions (probably ocular larva migrans originally). **95:** Systemic hypertensive disease associated with hyperadrenocorticism.

## BVA/KC/ISDS Eye Scheme Schedule A 2018

Alphabetical list of breeds and eye conditions for certification under the Inherited Eye Disease Status section of the Certificate of Examination (ie those specified in Schedule A of the current Procedure Notes and for which “Clinically Unaffected” or “Clinically Affected” boxes should be ticked):

- Alaskan Malamute – HC
- Australian Cattle Dog – PRA
- Australian Shepherd – HC
- Basset Hound – G, POAG
- Bedlington Terrier – TRD
- Belgian Shepherd Dog (all varieties) – HC
- Bichon Frise – HC
- Border Collie – CEA, RPED, PLL
- Boston Terrier – HC (two forms)
- Briard – RPED
- Bull Terrier (Miniature) – PLL
- Cavalier King Charles Spaniel – MRD, HC
- Collie (Rough) – CEA, PRA, RPED
- Collie (Smooth) – CEA, RPED
- Dachshund (Miniature Long-Haired) – PRA
- Dandie Dinmont Terrier – G
- Dobermann – PHPV
- Finnish Lapphund – PRA
- Fox Terrier (Smooth) – PLL
- Fox Terrier (Wire) – PLL
- German Shepherd Dog – HC
- Giant Schnauzer – HC
- Glen of Imaal Terrier – PRA
- Gordon Setter – PRA
- Hungarian Puli – MRD
- Irish Red and White Setter – HC
- Irish Setter – PRA
- Irish Wolfhound – PRA
- Japanese Shiba Inu – G
- Lancashire Heeler – CEA, PLL
- Large Munsterlander – HC
- Leonberger – G, HC
- Lhasa Apso – PRA
- Miniature Schnauzer – CHC, PRA, HC
- Norwegian Buhund – HC
- Norwegian Elkhound – PRA
- Old English Sheepdog – HC
- Parson Russell Terrier – PLL
- Petit Basset Griffon Vendeen – POAG
- Poodle (Miniature) – PRA
- Poodle (Standard) – HC
- Poodle (Toy) – PRA
- Retriever (Chesapeake Bay) – PRA, HC
- Retriever (Flat Coated) – G
- Retriever (Golden) – MRD, PRA, RPED, HC
- Retriever (Labrador) – MRD, TRD, PRA, RPED, HC
- Retriever (Nova Scotia Duck Tolling) – PRA
- Rottweiler – MRD
- Sealyham Terrier – TRD, PLL
- Shar Pei – POAG
- Shetland Sheepdog – CEA, RPED
- Siberian Husky – G, HC
- Spaniel (American Cocker) – MRD, G, PRA, HC,
- Spaniel (Cocker) – G, PRA, RPED
- Spaniel (English Springer) – MRD, G, PRA, RPED,
- Spaniel (Welsh Springer) – G, HC
- Spanish water Dog – G
- Staffordshire Bull Terrier – PHPV, HC
- Swedish Vallhund – PRA
- Tibetan Spaniel – PRA
- Tibetan Terrier – PRA, PLL
- Welsh Corgi (Cardigan) – PRA, RPED

**Inherited eye disease status (NB: For a number of breeds a DNA test is available for certain eye conditions – please refer to current list)**

CEA	=	Collie Eye Anomaly
CHC	=	Congenital Hereditary Cataract
G	=	Goniodysgenesis/Primary Glaucoma
HC	=	Hereditary Cataract
MRD	=	Multifocal Retinal Dysplasia
PLL	=	Primary Lens Luxation
PHPV	=	Persistent Hyperplastic Primary Vitreous
POAG	=	Primary Open Angle Glaucoma
PRA	=	Progressive Retinal Atrophy
RPED	=	Retinal Pigment Epithelial Dystrophy (formerly Central Progressive Retinal Atrophy = CPRA)
TRD	=	Total Retinal Dysplasia

## BVA/KC/ISDS Eye Scheme Schedule B 2018

Conditions under investigation (i.e those that are not yet included in Schedule A of the Procedure notes, but for which information is being actively sought by examination of the breeds for the conditions specified). These conditions should be commented upon only in the middle section of the eye certificate.

- Akita – PRA
- Australian Shepherd – C
- Beagle – MRD
- Bloodhound – MOD
- Border Collie – HC (early developing), G
- Border Terrier – HC (late onset)
- Bullmastiff – PPM
- Cairn Terrier – APD
- Cavalier King Charles Spaniel – MOD
- Collie (Rough) – MOD, MRD
- Dachshund (Miniature Long-Haired) – ONH
- Dachshund (Miniature Smooth-Haired) – PRA
- Dachshund (Miniature Wire-Haired) – PPM
- Dandie Dinmont Terrier – G
- Doberman – MOD
- Finnish Lapphund – MRD, PHPV, HC, PPM
- French Bulldog – HC (early developing)
- German Shepherd Dog – MRD
- German Spitz – MRD
- Giant Schnauzer – MRD
- Great Dane – G
- Greenland Dog – HC (early developing)
- Griffon Bruxellois – HC (early developing)
- Hungarian Vizsla – G
- Irish Setter – PRA (late onset)
- Lancashire Heeler – HC (early developing), PPM
- Norwegian Elkhound – MRD
- Old English Sheepdog – MOD, CHC
- Papillon – PRA
- Petit Basset Griffon Vendeen – PPM
- Polish Lowland Sheepdog – RPED
- Poodle (Miniature) – ONH
- Poodle (Standard) – MOD
- Poodle (Toy) – ONH
- Retriever (Flat Coated) – PRA
- Retriever (Golden) – MOD, CHC, G
- Retriever (Labrador) – APD
- Rottweiler – MOD, PPM
- Siberian Husky – PPM
- Spaniel (Cocker) – MOD, PPM
- Spaniel (Field) – HC (early developing), MRD
- Spaniel (Sussex) – MRD
- Staffordshire Bull Terrier – HC (variable age of onset)
- Tibetan Terrier – HC (early developing)
- Welsh Terrier – G
- West Highland White Terrier – MOD, CHC, PPM
- Yorkshire Terrier – HC (late onset), PRA

APD	=	Abnormal Pigment Deposition
C	=	Coloboma
CEA	=	Collie Eye Anomaly
CHC	=	Congenital Hereditary Cataract
G	=	Goniodysgenesis/Primary Glaucoma
HC	=	Hereditary Cataract
MOD	=	Multi-ocular defects
MRD	=	Multifocal Retinal Dysplasia
ONH	=	Optic Nerve Hypoplasia
PHPV	=	Persistent Hyperplastic Primary Vitreous
PLL	=	Primary Lens Luxation
PPM	=	Persistent Pupillary Membrane
PRA	=	Progressive Retinal Atrophy
RPED	=	Retinal Pigment Epithelial Dystrophy (formerly Central Progressive Retinal Atrophy (CPRA))

## Litter screening checklist BVA/KC/ISDS Eye Scheme synopsis sheet 2018

Alphabetical list of breeds and congenital inherited ocular diseases (those ophthalmoscopically identifiable during the neonatal stage) for those specified in Schedule A of the current Procedure Notes:

- Bedlington Terrier – TRD
- Border Collie – CEA
- Cavalier King Charles Spaniel – MRD
- Collie (Rough) – CEA
- Collie (Smooth) – CEA
- Doberman – PHPV
- Hungarian Puli – MRD
- Lancashire Heeler – CEA
- Miniature Schnauzer – CHC
- Retriever (Golden) – MRD
- Retriever (Labrador) – TRD, MRD
- Rottweiler – MRD
- Sealyham Terrier – TRD
- Shetland Sheepdog – CEA
- Spaniel (American Cocker) – MRD
- Spaniel (English Springer) – MRD
- Staffordshire Bull Terrier – PHPV

Congenital inherited ocular diseases	
CEA	= Collie Eye Anomaly
CHC	= Congenital Hereditary Cataract
PHPV	= Persistent Hyperplastic Primary Vitreous
TRD	= Total Retinal Dysplasia
MRD	= Multifocal Retinal Dysplasia

## Summary

- The BVA/KC/ISDS Eye Scheme offers a means of identifying the presence or absence of inherited eye disease in a variety of breeds of dog. There is little doubt that conscientious breeders of all types of dog, both purebred and crossbred, wish to use sound stock with known freedom from inherited eye disease and breed-related ocular disorders as part of their breeding programme. However, in the context of a comprehensive breeding programme, it is important to recognise that inherited problems without any impact on the dog's quality of life may well rank below maintaining genetic diversity and ensuring that breeding pairs are of good temperament and fit for function, an aspect of particular importance in working dogs. Understanding the welfare implications of inherited disease and breed-related ocular disorders is crucial and those conditions that may be a cause of pain or blindness, require surgical correction, or lifelong medical therapy should be regarded as priorities for elimination, as they have substantial effects on the individual's quality of life. All veterinary surgeons involved in clinical practice can help to achieve this ideal by:
  - Checking puppies' eyes when they are seen for the first time;
  - Informing all pet owners, not just breeders, about the Eye Scheme; and
  - Ensuring that owners recognise the need for eye examination in any dog which is to be used for breeding and are aware of the importance of annual examination for dogs used regularly for breeding.
- In addition, older dogs (those over eight years of age) should be examined, in order to ascertain the dog's status in relation to possible later onset inherited ocular conditions, any changes that may have occurred with pre-existing inherited ocular conditions and as a way of assessing ocular and general health.

Up to date information on the Eye Scheme, which includes the conditions certified in individual breeds and those under investigation (see tables) can be obtained from the BVA website.

## PART II

# DNA testing for inherited eye diseases

By Cathryn Mellersh

Most of the inherited eye diseases for which DNA tests are currently available are 'simple' or single gene diseases. This means that the disease is a result of a single mutation; no other genes or environmental factors are involved. For these diseases the results of DNA tests are easy to interpret and an individual dog's risk of developing the disease can be estimated with virtual certainty from the DNA test results. Most simple inherited eye diseases have a recessive mode of inheritance. Every dog has two copies of each gene, one inherited from the dam and one from the sire, so any individual dog has one of three possible genotypes with regard to each single gene disorder:

- *normal or clear*, with two normal copies of the relevant gene;
- *carrier*, with one normal copy of the relevant gene and one recessive, mutant copy;
- *genetically affected*, with two copies of the recessive mutation.

Recessive mutations cause a loss of function of a gene. Carriers that have inherited a single copy of the normal gene from one parent and a single copy of a mutant gene from the other parent usually have sufficient normal protein encoded by the normal gene to have healthy functioning eyes. It is only when a dog inherits a faulty gene from both parents that it becomes clinically affected. Consequently, if a mutation is recessive then dogs with zero (normal/clear) or one copy of the mutation (carriers) will remain clinically free of the disease, although carriers will pass the mutation onto around half of their offspring. Dogs with two copies of the mutation (genetically affected) will almost certainly develop the disease during their lifetime. The age at which dogs typically develop clinical signs depends on the disease so although a dog with two copies of a particular disease mutation is genetically affected from birth it may not become clinically affected until later in life. It follows, therefore, that a genetically affected dog may be clinically unaffected at the time it has an eye examination, especially if it is very young at the time. Some carriers can be identified by pedigree analysis, once an affected dog has been diagnosed; for example, the clinically normal parents of an affected puppy are both carriers, as are all the clinically normal offspring of clinically affected animals.

The past 10 years have seen remarkable progress in the field of canine molecular genetics. Since the publication of the canine genome sequence in 2004 the genetic tools available to researchers have become increasingly sophisticated and the ease with which mutations responsible for inherited eye diseases in dogs can be identified has increased accordingly. **Table 1** contains details of the genes that have been associated with inherited eye diseases in dogs to date. Once a particular mutation has been identified, it is usually a relatively simple task to develop a DNA test that can be used to determine an individual dog's genotype with respect to the disease. Worldwide there are now many facilities offering canine DNA tests. The process of DNA testing involves the submission of a sample of a dog's DNA to an appropriate testing laboratory. The DNA can usually be submitted as a simple cheek swab that an owner can take themselves, although some tests/laboratories may require a blood sample. The testing laboratory analyses the DNA for the presence or absence of the relevant mutation and will report back, usually within a few weeks, with the result (the dog's 'genotype').

DNA testing and eye examinations should be regarded as complementary; one does not replace the need for the other. During an eye examination the ophthalmologist examines the eye and adnexa, so will detect any ocular abnormality a dog may have. DNA tests, on the other hand, usually only detect a single, specific mutation, and cannot be used to detect all abnormalities a dog may be suffering from, or detect newly emerging conditions within a breed. For example, Golden Retrievers can suffer from three different forms of progressive retinal atrophy (PRA), known as i) progressive rod cone dystrophy (prcd), ii) Golden Retriever PRA 1 (GR\_PRA1) and iii) Golden Retriever PRA2 (GR\_PRA2). These diseases are caused by mutations in three different genes so a DNA test for prcd, for example, does not provide any information about a dog's risk of developing GR\_PRA1 or GR\_PRA2. Routine eye examination could detect the clinical signs of PRA, providing the dog was old enough to be showing clinical signs, but would not determine which form a dog was suffering from. DNA tests are able to detect carriers, which an eye examination cannot do and a DNA test can be used from birth to determine whether a dog is genetically affected, before it may have developed clinical signs of disease.

**Table 1**

**Genes associated with inherited eye disease in dogs**

Disease	Locus or Abbreviation	Gene	Breed (A) denotes that the breed is examined under Schedule A
Cone-rod dystrophy	CRD3	ADAM9	Glen of Imaal Terrier (A)
Primary open angle glaucoma	POAG	ADAMTS17	Basset Hound (A), Beagle, Petit Basset Griffon Vendeen (A), Shar Pei (A)
Primary lens luxation	PLL	ADAMTS17	Australian Cattle Dog, Chinese Crested Dog, Jagdterrier, Lancashire Heeler (A), the Miniature Bull Terrier (A), Jack Russell Terrier, Parson Russell Terrier (A), Patterdale Terrier, Rat Terrier, Sealyham Terrier (A), Tenterfield Terrier, Tibetan Terrier (A), Fox Terrier (A), Volpino Italiano, Welsh Terrier, Wire-haired Fox Terrier (A), Yorkshire Terrier



Disease	Locus or Abbreviation	Gene	Breed (A) denotes that the breed is examined under Schedule A
Rod cone degeneration	RCD4	<i>C2orf71</i>	Gordon Setter (A), Irish Setter (A), Tibetan Terrier (A)
Generalised progressive retinal atrophy	gPRA	<i>CCDC66</i>	Schappendoes
Macular corneal dystrophy	MCD	<i>CHST6</i>	Labrador Retriever
Progressive retinal atrophy	PRA	<i>CNGB1</i>	Papillon
Cone degeneration	CD	<i>CNGB3</i>	Alaskan Malamute
Cone degeneration	CD	<i>CNGB3</i>	German Shorthaired Pointer
Dwarfism with retinal dysplasia (oculoskeletal dysplasia)	DRD2 (OSD2)	<i>COL9A2</i>	Samoyed
Dwarfism with retinal dysplasia (oculoskeletal dysplasia)	DRD1 (OSD1)	<i>COL9A3</i>	Labrador Retriever
Hereditary cataract	HC, EHC	<i>HSF4</i>	Staffordshire Bull Terrier (A), Boston Terrier (A), French Bulldog
Hereditary cataract	HC	<i>HSF4</i>	Australian Shepherd (A)
Collie eye anomaly	CEA	<i>NHEJ1</i>	Rough Collie (A), Smooth Collie (A), Border Collie (A), Shetland Sheepdog (A), Lancashire Heeler (A)
Cone-rod dystrophy		<i>NPHP4</i>	Standard Wire-Haired Dachshund
Photoreceptor dysplasia	PD	PDC	Miniature Schnauzer (A)
Rod cone dysplasia	RCD1	<i>PDE6B</i>	Irish Setter (A)
Rod cone dysplasia	RCD1	<i>PDE6B</i>	Sloughi
Rod cone dysplasia	RCD3	<i>PDE6A</i>	Cardigan Welsh Corgi (A)
Progressive rod-cone degeneration	PRCD	PRCD	Multiple breeds, including Australian Cattle Dog (A), American Cocker Spaniel (A), Cocker Spaniel (A), English Springer Spaniel (A), Rough Collie (A), Chesapeake Bay Retriever (A), Miniature Poodle (A), Toy Poodle (A), Golden Retriever (A), Labrador Retriever (A)
Rod cone dysplasia	RCD2	<i>RD3</i>	Rough Collie (A), Smooth Collie (A)
Autosomal dominant progressive retinal atrophy	ADPRA	<i>RHO</i>	Bull Mastiff, English Mastiff
Congenital stationary night blindness	CSNB	<i>RPE65</i>	Briard (A)
X-linked progressive retinal atrophy	XLPR2	<i>RPGR</i>	Mixed breed dogs
X-linked progressive retinal atrophy	XLPR1	<i>RPGR</i>	Siberian Husky, Samoyed
Cone-rod dystrophy	CORD1 (CRD4)	<i>RPGRIP</i>	Miniature longhaired Dachshund (A)
Progressive retinal atrophy	GR_PRA1	<i>SLC4A3</i>	Golden Retriever (A)
Early retinal degeneration	ERD	<i>STK38L</i>	Norwegian Elkhound (A)
Progressive retinal atrophy	GR_PRA2	<i>TTC8</i>	Golden Retriever (A)
Canine multifocal retinopathy	CMR1	<i>VMD2/BEST1</i>	Great Pyrenees, English Mastiff, and Bullmastiff dogs
Canine multifocal retinopathy	CMR2	<i>VMD2/BEST1</i>	Coton de Tulear
Canine multifocal retinopathy	CMR3	<i>VMD2/BEST1</i>	Lapponian Herder
Progressive retinal atrophy	PRA	<i>MERTK</i>	Swedish Vallhund

Dogs that are to be used for breeding should have all DNA tests that are relevant to their breed (unless they are hereditarily clear, see Recording Results). They should also be examined and certified under the Eye Scheme, prior to breeding and subsequently, as outlined in the introduction to this pamphlet, including a final examination when the dog is over eight years of age. In those breeds in which inherited congenital/neonatal eye diseases are known or suspected it may also be sensible to carry out litter screening of puppies as outlined earlier.

Dogs that are carriers of disease mutations can be bred from safely. Provided all carriers are paired with DNA-tested, clear mates only clear and carrier puppies will be born; no clinically affected dogs will be produced and breeders can select a clear dog to breed on from the resulting litters. **Table 2** details the outcomes of mating dogs with different genotypes (with respect to a recessive mutation) and whether they can result in clinically affected offspring.

**Table 2****Recessive inheritance—expected outcomes of breeding combinations**

Combination of Dogs	Outcome	Possibility of clinically affected offspring?
Clear X Clear	All puppies will be clear	No
Clear X Carrier	Approx. 50% of puppies will be clear Approx. 50% of puppies will be carriers	No
Clear x Affected	All puppies will be carriers	No
Carrier x Carrier	Approx. 25% of puppies will be clear Approx. 25% of puppies will be affected Approx. 50% of puppies will be carriers	Yes
Carrier x Affected	Approx. 50% of puppies will be affected Approx. 50% of puppies will be carriers	Yes
Affected x Affected	All puppies will be affected	Yes

**Recording results**

Eye examination results for all Schedule A conditions are recorded in the Kennel Club's Registration Database, with the information being added to the relevant field of the dog's record. A similar process is in place to deal with the results of DNA testing for inherited eye disease. Breed clubs that have one or more DNA test are encouraged to establish an Official DNA Testing Scheme for the condition(s), whereby the DNA test results for individual dogs are sent directly to the Kennel Club and are added to the dog's registration data. For those puppies resulting from two DNA "clear" tested dogs, an automatic status of "hereditarily clear" is assigned and published as described below.

For breeds examined under the Scheme that are not included in Schedule A, where the dog is registered with the Kennel Club, a note will be added to the dog's record on the Kennel Club's database confirming that an examination has taken place and the date of the examination.

The addition of health screening results to the Kennel Club Registration Database triggers dissemination via a number of different routes. The result(s) will appear:

- On any new registration certificate issued for the dog;
- On the registration certificates of any of the dog's future progeny;
- In the Kennel Club Breed Records Supplement (BRS), a quarterly publication.

The Kennel Club also maintains lists of DNA test results for all Official DNA Testing Schemes on the health pages of its website ([www.thekennelclub.org.uk](http://www.thekennelclub.org.uk)).

**Appeals procedure****Eye Examination Certificate**

Any appeal against the results of an eye examination must be lodged in writing with the British Veterinary Association (BVA) **within 30 days** of the examination. BVA's address is shown overleaf.

The owner may then take the dog, together with the certificate issued by the first panellist, for examination by the Chief Panellist, a panellist from the Eye Panel Working Party, or another panellist. The second panellist will charge the normal fee. If the second panellist agrees with the first panellist the appeal will be deemed to have failed and the second panellist will inform BVA accordingly. In such an event no further appeal is possible.

The decision of the Chief Panellist at second examination is final, as also is the decision of a panellist from the Eye Panel Working Party acting in consultation with the Chief Panellist and provided that the Chief Panellist agrees with the findings reported. In all other circumstances, if the second panellist disagrees with the first panellist the dog shall be referred to the Chief Panellist for further examination without additional fee to the owner. The decision of the Chief Panellist will be final and the Chief Panellist will advise BVA of the result accordingly. Owners may choose to see the Chief Panellist as the second panellist once an appeal has been lodged with BVA. If so, the normal fee will be charged.

The final result of any appeal must be received by BVA **within 90 days** of examination, otherwise the first result may be sent to the Kennel Club and/or the International Sheep Dog Society for publication.

**Litter Screening Eye Examination Certificate**

Any appeal against the results of litter screening must be notified to BVA and/or Chief Panellist as soon as possible so that suitable arrangements may be made for the whole litter to be re-examined before the puppies reach 12 weeks of age. No appeal will be granted unless all the puppies are re-examined on the same occasion and the puppies are less than 12 weeks of age.

# BVA/KC/ISDS CHS Eye Scheme

Panel of Examiners as at July 2019

Chief Panellist: Professor Peter Bedford

## England

### **Professor P G C Bedford BVetMed PhD DVOphthal DipECVO FHEA FRCVS**

Village Vets Cayton  
601 Hatfield Road, Smallford  
Hertfordshire AL4 0HL  
Telephone 01727 852667

### **B T Blacklock BVSc(Hons) DipECVO MRCVS**

Dick White Referrals  
Station Farm, London Road, Six Mile Bottom  
Cambridgeshire CB8 0UH  
Telephone 01638 572012

### **N J Burden BVSc CertVOphthal MRCVS**

The Hale Veterinary Group  
19 Langley Road, Chippenham  
Wiltshire SN15 1BS  
Telephone 01249 653561

### **J Carter BVetMed DVOphthal DipECVO MRCVS**

South Devon Referrals  
The Old Cider Works, Abbotskerswell  
Newton Abbot  
Devon TQ12 5GH  
Telephone 01626 367972

### **Mrs B Cottrell MA VetMB CertVOphthal MRCVS**

109 North End  
Meldreth, Royston  
Hertfordshire SG8 6NX  
Telephone 01763 261674

### **Professor S M Crispin MA VetMB BSc PhD DVA DVOphthal DipECVO FRCVS**

Cold Harbour Farm  
Underbarrow, Kendal  
Cumbria LA8 8HD  
Telephone 020 7908 6380  
Telephone (home) 01539 568637

### **S R Ellis BVSc CertVOphthal MRCVS**

Riverbank Veterinary Centre  
16/22 Watery Lane, Preston  
Lancashire PR2 2NN  
Telephone 01772 726745

### **Miss H J Featherstone BVetMed DVOphthal DipECVO MRCVS**

The Ralph Veterinary Referral Centre  
Fourth Avenue, Globe Business Park  
Marlow SL7 1YG  
Telephone 0800 689 4298

### **K J Fraser BVM&S CertVOphthal MRCVS**

The Anima Veterinary Clinic  
Church Road, Iwer Heath  
Buckinghamshire SL0 0RA  
Telephone 01753 911300

### **G V Fricker BVSc CertVOphthal Dip ECVO MRCVS**

Davies Veterinary Specialists  
Manor Farm Business Park  
Higham Gobion  
Hertfordshire SG5 3HR  
Telephone 01582 883950

### **J V Goodyear BVMS CertVOphthal MRCVS**

29 Park Road  
Barton-under-Needwood  
Staffordshire DE13 8DW  
Telephone 01283 713359

### **Dr D J Gould BVM&S BSc (Hons) PhD DVOphthal DipECVO FRCVS**

Davies Veterinary Specialists  
Manor Farm Business Park, Higham Gobion  
Hertfordshire SG5 3HR  
Telephone 01582 883950

### **R Grundon BSc VetMB CertVR CertVOphthal MANZCVS (Surgery) FANZCVS (Ophthal) FRCVS**

Eye Veterinary Clinic  
Marlbrook, Leominster  
Herefordshire HR6 0PH  
Telephone 01568 616616

### **D Habin BVMS DVOphthal MRCVS**

Paragon Veterinary Referrals  
1 Red Hall Crescent  
Paragon Business Village, Wakefield  
West Yorkshire, WF1 2DF  
Telephone 01924 908333

### **C Hartley BVSc CertVOphthal DipECVO MRCVS**

Small Animal Hospital  
Langford Vets, Langford  
Bristol BS40 5DU  
Telephone 0117 394 0513

### **Miss C L Heinrich DVOphthal DipECVO MRCVS**

Eye Veterinary Clinic  
Marlbrook, Leominster  
Herefordshire HR6 0PH  
Telephone 01568 616616

### **C Kafarnik Dr MedVet DipECVO MRCVS**

The Animal Health Trust  
Lanwades Park, Kentford, Newmarket  
Suffolk CB8 7UU  
Telephone 01638 552700

### **M P C Lawton BVetMed CertVOphthal CertLAS CBiol MIBiol DZooMed FRCVS**

12 Fitzilain Avenue  
Harold Wood, Romford  
Essex RM3 0QS  
Telephone 01708 384444

### **R Linn-Pearl BVSc DipECVO MRCVS**

Eye Veterinary Clinic  
Marlbrook, Leominster, Herefordshire, HR6 0PH  
Telephone 01568 616616

### **R C Lowe BVSc DVOphthal MRCVS**

Optivet Referrals Ltd  
3 Downley Road, Havant  
Hampshire PO9 2NJ  
Telephone 01243 888091

### **Miss S P Manning BVSc CertVOphthal DVOphthal MRCVS**

Pride Veterinary Centre  
Riverside Road, Pride Park  
Derby DE24 8HX  
Telephone 01332 678333

### **P McPherson BVMS CertVOphthal MRCVS**

Minster Veterinary Centre  
Orchard Lodge, Newark Road, Southwell  
Nottinghamshire NG25 0ES  
Telephone 01636 812133

### **I K Mason MA VetMB CertVOphthal MRCVS**

Seadown Veterinary Hospital  
Frost Lane, Hythe  
Hampshire SO45 3NG  
Telephone 023 8084 2237/01590 679921

### **J R B Mould BA BVSc DVOphthal MRCVS**

Eye Veterinary Clinic, Marlbrook, Leominster  
Herefordshire HR6 0PH  
Telephone 01568 616616

### **Mrs L J Newman BVM&S CertVOphthal MRCVS**

West Midlands Referrals  
Errisbeg House, Barton Turn  
Barton Under Needwood, Burton-on-Trent  
Staffordshire DE13 8EB  
Telephone 01543 414248

### **J Oliver BVSc CertVOphthal DipECVO MRCVS**

Dick White Referrals  
Station Farm, London Road, Six Mile Bottom  
Cambridgeshire CB8 0UH  
Telephone 01638 572012

### **R Pontefract BVMS CertVOphthal MRCVS**

43 Empingham Road, Stamford  
Lincolnshire PE9 2RJ  
Telephone 01780 764333

### **M Rhodes BVM&S CertVOphthal DipECVO MRCVS**

Website: [www.focusreferrals.co.uk](http://www.focusreferrals.co.uk)  
Email: [info@focusreferrals.co.uk](mailto:info@focusreferrals.co.uk)

### **Ms K Smith BVetMed CertVOphthal DipECVO MRCVS**

Davies Veterinary Specialists  
Manor Farm Business Park, Higham Gobion  
Hertfordshire SG5 3HR  
Telephone 01582 883950

### **Ms S Turner MA VetMB DVOphthal MRCVS**

The Mandeville Veterinary Hospital  
15 Mandeville Road  
Northolt UB5 5HD  
Telephone 020 8845 5677

### **C G B WARREN BA VetMB CertVOphthal MRCVS**

Westmoor Veterinary Centre  
Brook Lane, Tavistock, Devon PL19 9BA  
Telephone 01822 612561

### **J Yellowley BVSc CertVOphthal MRCVS**

St. Clair Veterinary Care  
87 Bridge Street, Blyth  
Northumberland NE24 3AE  
Telephone 01670 457271

## Scotland

### **M G Davidson BVM&S CertVOphthal MRCVS**

19 Hillhouse Road  
Edinburgh EH4 3QP  
Telephone 0131 332 0458

### **A T McKenzie BVMS CertVOphthal MRCVS**

MBM Veterinary Group  
21 Hill Street, Kilmarnock  
Ayrshire KA3 1HF  
Telephone 01563 522701

### **A E Wall BVM&S CertVOphthal MSc MRCVS**

Scottish Vet Referrals  
14a Inverness Campus  
Inverness IV2 5NA  
Telephone 01463 21882

## Wales

### **H Cormie BVMS CertVOphthal MRCVS**

Cormie Referrals  
Ty Pen-y-Coed, Glangrwyney, Crickhowell  
Powys NP8 1EW  
Telephone 07813 197222

### **Mrs G E Hubbard BVetMed CertVOphthal MRCVS**

Cibyn Veterinary Clinic  
Llanberis Road, Caernarfon  
Gwynedd LL55 2BD  
Telephone 01286 673026

## Northern Ireland

### **I Millar BVMS CertVOphthal MRCVS**

Earlwood Veterinary Hospital  
193 Belmont Road  
Belfast BT4 2AE  
Telephone 028 9047 1361

## Ireland

### **Dr T D Grimes BVetMed PhD DVR DVOphthal DipECVO MRCVS**

Department of S A Clinical Studies  
Faculty of Veterinary Medicine  
University College Dublin  
Belfield  
Dublin 4, Ireland  
Telephone: + 353 1 716 6022

### **N Mitchell MVB DVOphthal MRCVS**

Eye Vet, Crescent Veterinary Clinic  
Doora Doyle Road  
Limerick  
Ireland  
Telephone: + 353 61 301 841



### Canine Health Schemes

7 Mansfield Street, London W1G 9NQ  
Tel: 020 7908 6380 Fax: 020 7908 6389  
Email: [chs@bva.co.uk](mailto:chs@bva.co.uk)  
[www.bva.co.uk/chs](http://www.bva.co.uk/chs)



### International Sheep Dog Society

Clifton House, 4a Goldington Road  
Bedford MK40 3NF  
Tel: 01234 352672 Fax: 01234 348214  
Email: [office@isds.org.uk](mailto:office@isds.org.uk)



### The Kennel Club

10 Clarges Street, London W1J 8AB  
Telephone 0844 4633 980  
[hbs@thekennelclub.org.uk](mailto:hbs@thekennelclub.org.uk)  
[www.thekennelclub.org.uk/doghealth](http://www.thekennelclub.org.uk/doghealth)